

COMPARATIVE ANALYSIS OF THE EFFICIENCY OF DIFFERENT METHODS OF OSTEOTOMY WHEN PERFORMING CLOSED RHINOPLASTY

Oleksandr O. Karchynskyi¹, Andriy V. Lupyr¹, Tetiana O. Karchynska²

1 – Department of Otorhinolaryngology, Kharkiv National Medical University, Kharkiv, Ukraine

2 – Communal Non-Commercial Enterprise «City Polyclinic № 22» of the Kharkiv City Council, Kharkiv, Ukraine

Summary

The aim. Increasing the effectiveness of treatment of patients with primary deformity of the nasal skeleton with a pronounced violation of the function of nasal breathing, by improving existing and developing new methods of reconstructive surgery of the nose.

Materials and methods. 38 patients participated in the study. They were divided into two groups of 19 patients each. The gender and age distribution in both groups was approximately the same. The control group had rhinoplasty performed using a traditional osteotomy. Endonasal continuous osteotomy was performed using a 4 mm chisel. The research group underwent a combination of piezoelectric surgery and combined transcutaneous access, during rhinoplasty. At the same time, a 3 mm chisel was used for lateral and transverse lateral osteotomies, and a piezotome was used to remove the hump, medial and transverse dorsal osteotomies. All patients of both groups underwent only primary rhinoplasty in a closed manner.

Results. Postoperative symptoms and complications were studied in both groups: perforation of the mucous membrane, narrowing of the nasal airways, bony irregularities, eyelid swelling, periorbital ecchymoses, as well as overall patient satisfaction. Symptoms were evaluated on the first day after surgery, 3 days after surgery, and 1 week after treatment. When comparing the obtained data, a statistically significant decrease in intra- and post-operative complications was found when performing rhinoplasty using piezoelectric surgery in combination with transcutaneous access. Also, piezotome osteotomy in combination with transcutaneous access has a number of advantages over classic osteotomy, which consist in reducing traumatic complications, obtaining more stable bone structures during surgery, which gives a better predicted result of rhinoplasty, and therefore, greater patient satisfaction.

Conclusions. Performing a combination of piezotome osteotomy with a transcutaneous approach improves the postoperative period for patients and contributes to a better rhinoplasty result due to fewer complications.

Key words: piezotome, osteotomy, rhinoplasty, transcutaneous, endonasal, complication

INTRODUCTION

Piezoelectric osteotomy is based on the mechanical effect of ultrasound, which is enhanced by the physical phenomenon of cavitation. Thanks to the microvibration of the ultrasonic frequency, it is possible to perform a selective bone incision without significant damage to the underlying soft tissue and neurovascular bundles [1].

Piezoelectric surgery is considered a relatively new alternative to bone procedures in craniofacial surgery [6,

13]. The ability to obtain a precise osteotomy without significant damage to soft tissues is a key point in modern approaches to rhinoplasty [10].

Rhinoplasty is a frequently performed operation to correct the deformity of the nose. An important stage of the rhinoplasty operation is the formation of the bone structures of the nose [2, 3]. Osteotomy is a means of straightening the bony part of the nose [10]. Each osteotomy technique has its own disadvantages and advantages, such as uncontrolled fractures, soft tissue

damage, and as a result – undesirable postoperative complications and a long recovery period, which spoil the aesthetic appearance and functional result [8].

The advantages of using this or that method of lateral osteotomy have been studied by many authors [5, 7, 9], however, research data are somewhat contradictory and there is no consensus and conclusions about the advantage of using this or that method, so the study of this issue remains relevant.

THE AIM OF THE STUDY

Increasing the effectiveness of treatment of patients with primary deformity of the nasal skeleton with a pronounced violation of the function of nasal breathing, by improving existing and developing new methods of reconstructive surgery of the nose.

MATERIALS AND METHODS

A prospective study was conducted, with the addition of examination and treatment data of 38 patients. The division into groups was carried out as follows:

- control group (19 people). This group included patients who underwent rhinoplasty using a traditional osteotomy.

- research group (19 people). In this group of patients, piezoelectric surgery with a combined transcutaneous approach was used for rhinoplasty.

In the first group of patients (control group), traditional osteotomy was performed during closed rhinoplasty. Endonasal continuous osteotomy was performed using a 4 mm chisel.

In the second group of patients (research group), transcutaneous lateral osteotomy and piezotome osteotomy were combined during rhinoplasty. At the same time, a 3 mm chisel was used for lateral and transverse lateral osteotomies, and a piezotome was used to remove the hump, medial and transverse dorsal osteotomies.

The age of the patients ranged from 24 to 50 years. The gender and age distribution in both groups was approximately the same.

The study was conducted at the clinical base of the Department of Otorhinolaryngology of KhNMU in the Department of Head and Neck Surgery in the period 2020-2022.

All patients of both groups underwent only primary rhinoplasty in a closed manner. The study included patients without a history of nasal trauma and primary rhinoplasty. Persons with systemic diseases and those taking anticoagulants were also an exclusion group. *All patients signed an informed consent.*

Piezoelectric surgery was performed using a Japanese VarioSurg3 NSK piezotome.

Statistical data processing was performed on a personal computer using Microsoft Excel spreadsheets. The median (Me), 95 % confidence interval was determined for each quantitative parameter. Student's t-test, Spearman's correlation test were used to compare numerical data. Differences at $p < 0.05$ (95 % significance level) were considered statistically significant. Assessment of study quality was based on a double-blind randomized controlled trial.

RESULTS

The nurse, the patient, and the doctor, who did not know how the surgical intervention was performed, were involved in evaluating the results of the operation.

With the help of an endoscope (1) and visually (2), the doctor assessed:

- perforation of the mucous membrane¹
- narrowing of nasal airways¹
- bone irregularities²

Evaluation of the endoscopic picture and visual evaluation of indicators was carried out on the 3rd day after surgery.

Other symptoms were assessed using visual scales:

- swelling of the eyelids
- periorbital ecchymoses

Symptoms were evaluated on the first day after surgery, 3 days after surgery, and 1 week after treatment.

The general satisfaction of the patient was also studied with the help of the questionnaire «Evaluation of the results of rhinoplasty».

When evaluating the endoscopic picture, a picture of mucosal damage was obtained in two groups with a percentage of 89.5 % and 10.5 %, respectively, in the control group and the study group. At the same time, in the first group in which endonasal osteotomy was used, the extent of damage was greater. The difference between the signs reached statistical significance ($p < 0.001$).

Narrowing of the nasal airways had the following distribution: 73.7 % in the group of patients who underwent endonasal continuous osteotomy, versus 29.8 % in the group of patients who used transcutaneous osteotomy during rhinoplasty. The difference between the signs reached statistical significance ($p = 0.04$).

A scoring system was used to assess bone irregularities, where:

- Grade 1: there is no visible or palpable step on the lateral wall of the nose – 0 points.
- 2nd degree: a noticeable step on the side wall of the nose – 1 point.
- Grade 3: visible and palpable step on the side wall of the nose – 2 points.

The sum of points in the first group (control group) was higher and equal to 17, with an average value of 0.89 ± 0.19 . This corresponded to 29.8 %. At the same time, in the study group, the sum was equal to 10 points, with an average value of 0.59 ± 0.17 , which corresponded to 17.5 %. However, the difference between the signs did not reach statistical significance ($p=0.2$).

Visually, the difference in the estimated symptoms can be seen in the diagram (fig. 1).

Eyelid swelling was assessed on a 4-point visual scale (fig. 2).

- 1st degree – there is no covering of the iris by the eyelids;

- 2nd degree – slight covering of the iris by swollen eyelids;
- 3rd degree – full coverage of the iris by swollen eyelids;
- 4th degree – complete closure of the eye.

Eyelid ecchymosis was assessed using a 3-point visual scale (fig. 3).

- 1st degree (I) – ecchymosis to the medial third of the lower and/or upper eyelid;
- Ecchymosis of the 2nd degree (II) – to the medial 2/3 of the lower and/or upper eyelid;
- Grade 3 (III) – ecchymoses along the entire length of the lower and/or upper eyelid.

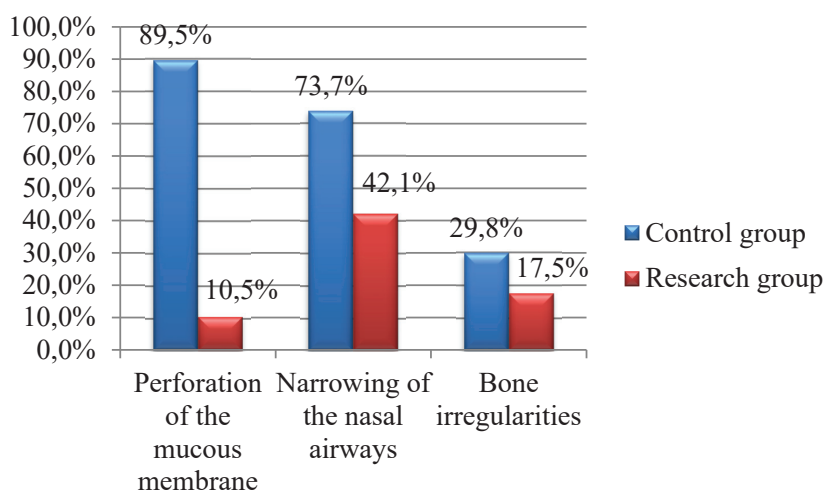


Fig. 1. Endoscopic and visual assessment of intraoperative complications during intranasal and transcutaneous osteotomy on the 3rd day after surgery

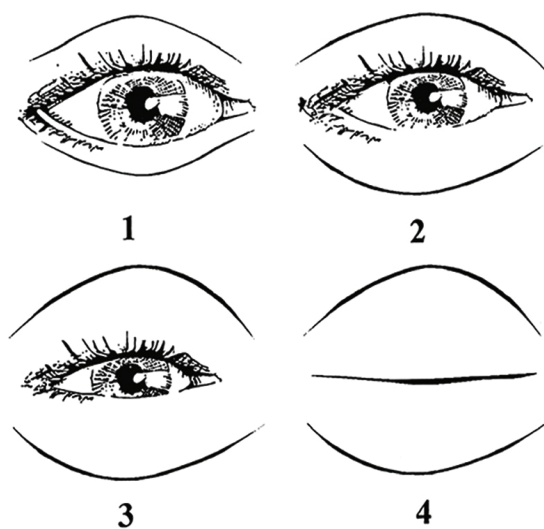


Fig. 2. Visual scale for evaluating eyelid swelling

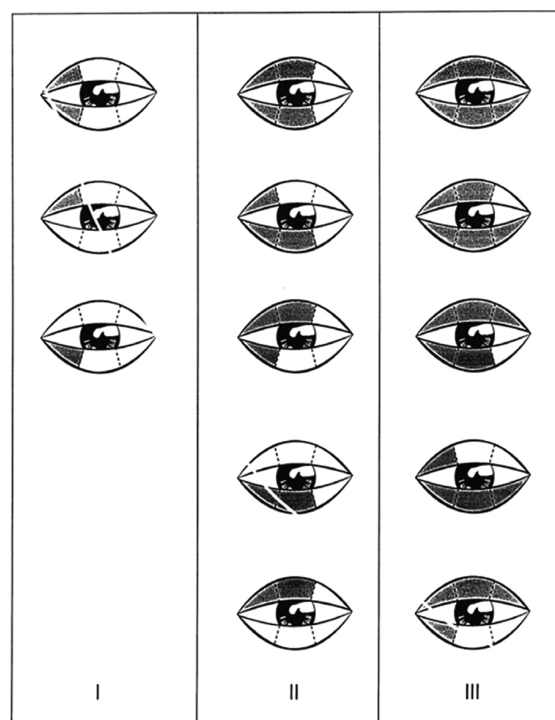


Fig. 3. Visual scale for evaluating eyelid ecchymosis

Swelling and ecchymoses of the eyelids were noted in both groups of patients (Table 1). On the first day after the operation, the swelling of the eyelids in patients who underwent rhinoplasty with the help of classical osteotomy was estimated at 2.11 ± 0.17 , but in the second group of patients who underwent rhinoplasty by a combined method (piezoelectric surgery with transcutaneous osteotomy) – at 1.37 ± 0.19 points ($p < 0.001$). Eyelid ecchymoses were 1.68 ± 0.15 and 1.26 ± 0.17 , respectively. Despite the fact that the level of ecchymoses was higher in the first group, it did not reach statistical significance ($p = 0.07$).

On the third day, swelling and ecchymoses of the eyelids increased in both groups and already had indicators of 3.32 ± 0.17 against 2.58 ± 0.21 , when evaluating the swelling of the eyelids (Student's t-test value: 2.74, critical value of the t-test Student's = 2.028, indicators statistically significant < 0.001), and 2.42 ± 0.16 versus 1.84 ± 0.14 , when evaluating ecchymoses (Student's t-test value: 2.73, critical value of Student's t-test = 2.028, indicators statistically significant < 0.001).

By the seventh day, both indicators decreased in both groups, while their level in the first group (control group) remained higher.

Table 1

Score evaluation of swelling and ecchymoses of the eyelids in two groups on the first, third and seventh day after rhinoplasty

GPA		Control group		Research group		P
		$\pm \sigma$	GPA	$\pm \sigma$		
Swelling of the eyelids	1 day	2,11	0,17	1,37	0,19	<0,001
	3 day	3,32	0,17	2,58	0,21	<0,001
	7 day	1,26	0,17	0,84	0,18	0,09
Ecchymosis of the eyelids	1 day	1,68	0,15	1,26	0,17	0,07
	3 day	2,42	0,16	1,84	0,14	<0,001
	7 day	1,26	0,17	0,63	0,14	<0,001

The overall satisfaction of patients with the performed operation was assessed using the questionnaire «Evaluation of the results of rhinoplasty». The questionnaire included 5 questions related to general feeling after surgery, assessment of postoperative symptoms, and appearance. Patients answered each question on a scale from 0 to 4, where 0 was the most negative response and 4 was the most positive response. The patients' answers to each question were summed up, and the resulting sum was divided by 20 and multiplied by 100. Thus, a score from 0 % (minimum satisfaction) to 100 % (maximum satisfaction) was obtained.

The results of the test revealed an increase in the level of satisfaction in the second group to 70 ± 1 %, compared to 58.4 ± 2.4 % ($p < 0.001$) in the first group of patients.

DISCUSSION

Piezotome osteotomy has a number of advantages over classical osteotomy, which primarily consist in reducing the traumatization of the underlying tissues, reducing the risk of osteonecrosis and damage to the periosteum and cartilage located under the bone structures, controlled work with the bone structures of the nose, prevention of the formation of splintered and radiating bone fragments, especially when working with thin bones. Giancarlo Tirelli and others [12] studied the performance of osteotomy by piezoelectric and classical methods and as a result, osteotomy using a piezotome was more accurate, linear and effective, especially when working with thick bone components, and there were no «green twig» type fractures. In our work, we also obtained similar results.

Mahdi Gholami and others. compared external and internal lateral osteotomy and came to the conclusion that on 2, 7 and 21 days of observation there is no significant difference between the two methods in the study of the most frequent postoperative complications [4]. Sadrollah Motamed and others in their work also did not note the difference between postoperative symptoms in the groups with internal and external osteotomy [8]. In our study, traditional osteotomy and the combined technique of piezoelectric and transcutaneous osteotomy were compared, while the results of ecchymosis and swelling of the eyelids were evaluated on days 1, 3, and 7, and a statistically significant difference was found between both symptoms on day 3 after surgery. Transcutaneous osteotomy allows you to easily obtain a bone fracture in a given area with high accuracy, while the presence of bone fragments at the fracture sites is significantly reduced, compared to classical osteotomy. At the same time, the probability of bleeding decreases, thanks to a controlled bone fracture, the absence of massive trauma to soft tissues and vessels, the absence of accidental perforation of the mucous membrane, and postoperative complications, such as swelling around the eyes and ecchymoses, are reduced with statistical reliability, which is confirmed by the data of other authors [7, 11].

Performing a transcutaneous approach provides a partial separation of soft tissues, in contrast to a classic osteotomy, which allows the use of a more stable, fixed bone structure during surgical intervention and fixation of fragments, thus providing a more stable bone frame and a better predicted result of rhinoplasty and, therefore, a greater patient satisfaction with both the postoperative rehabilitation period and the appearance of the obtained result.

The skin incision during transcutaneous access heals with an imperceptible scar, which also has a positive effect on patient satisfaction with the surgical intervention.

CONCLUSIONS

1. The combined method of osteotomy (piezoelectric and transcutaneous osteotomy) has significantly lower levels of intra- and postoperative complications ($p < 0.05$) and a better recovery period, compared to traditional osteotomy.

2. Transcutaneous osteotomy has a number of advantages over intranasal continuous osteotomy in more accurate execution of the bone fracture and reduction of

complications from the surgical intervention, such as periorbital ecchymoses and eyelid edema ($p < 0.05$).

COMLIANCE WITH ETHICAL REQUIREMENTS, FUNDING AND CONFLICT OF INTEREST

The published study met guidelines for human subjects research and was conducted in accordance with the World Medical Association's Declaration of Helsinki. The authors declare that the study was conducted in the absence of any commercial or financial relationship that could be interpreted as a potential conflict of interest. The article is self-funded.

REFERENCES

- Bloom, J.D., Immerman, S.B., Constantinides, M. (2011). Osteotomies in the crooked nose. *Facial Plast Surg.*, 27(5), 456-466. DOI: 10.1055/s-0031-1288927
- Crovace, A.M., Luzzi, S., Lacitignola, L., Fatone, G., Lucifero, A.G., Vercellotti, T., Crovace, A. (2020). Minimal Invasive Piezoelectric Osteotomy in Neurosurgery: Technic, Applications, and Clinical Outcomes of a Retrospective Case Series. *Vet Sci.*, 7(2), 68. DOI: 10.3390/vetsci7020068
- Fallahi, H.R., Keyhan, S.O., Fattahi, T., Mohiti, A.K. (2019). Comparison of piezosurgery and conventional osteotomy post rhinoplasty morbidities: A double-blind randomized controlled trial. *J Oral Maxillofac Surg.*, 77(5), 1050-1055. DOI: 10.1016/j.joms.2019.01.004
- Ghavimi, M.A., Nezafati, S., Yazdani, J., Pourlak, T., Amini, M., Poulak, T., Ghoreishizadeh, A., Negahdari, R. (2018). Comparison of edema and ecchymosis in rhinoplasty candidates after lateral nasal osteotomy using piezosurgery and external osteotomy. *J Adv Pharm Technol Res.*, 9(3), 73-79. DOI: 10.4103/japtr.JAPTR_294_18
- Gholami, M., Vaezi, A. (2019). Comparison of the Effects of External and Internal Lateral Nasal Osteotomies on Ecchymosis, Periorbital Edema, and Step off Deformity After Rhinoplasty. *World J Plast Surg.*, 8(3), 345-351. DOI: 10.29252/wjps.8.3.345
- Jeong, J.Y., Ha, Y., Kim, S., Yang, H.J., Oh, S.H. (2018). Availability and Safety of Osteotomy in Esthetic Rhinoplasty of East Asian Patients. *Ann Plast Surg.*, 81(2), 141-145. DOI: 10.1097/SAP.0000000000001472
- Karchynskiy, O.O., Karchynska, T.O., Lupyr, A.V. (2022). Assessment of the efficiency of piezoelectric and classic osteotomy when performing septorhinoplasty. *Wiad Lek.*, 75(1), 2594-2597. DOI: 10.36740/WLek202211107
- Khalaf, A.Q., Taher, F.S., Khudhair, H.M. (2017). Comparism Study between Internal & External Lateral Osteotomy in Rhinoplasty Operations. *J Otolaryngol ENT Res.*, 6(2), 68-69. DOI: 10.15406/joentr.2017.06.00159
- Motamed, S., Saberi, A., Niazi, F., Molaei, H. (2017). Complications of Internal Continuous and Perforating External Osteotomy in Primary Rhinoplasty. *World J Plast Surg.*, 6(2), 164-169.
- Öğreden, S., Rüzgar, S., Tansuker, H.D., Tas, Kın, Ü., Alimoglu, Y., Aydın, S., Oktay, M.F., İzol, U. (2018). Histopathological comparison of bone healing effects of endonasal and percutaneous lateral osteotomy methods in rabbit rhinoplasty model. *Braz J Otorhinolaryngol.*, 84(5), 540-544. DOI: 10.1016/j.bjorl.2017.06.008
- Robiony, M., Lazzarotto, A., Nocini, R., Costa, F., Sembronio, S., Franz, L. (2019). Piezosurgery: Ten Years' Experience of Percutaneous Osteotomies in Rhinoplasty. *J Oral Maxillofac Surg.*, 77(6), 1237-1244. DOI: 10.1016/j.joms.2019.01.035
- Sinha, V., Gupta, D., More, Y., Prajapati, B., Kedia, B.K., Singh, S.N. (2007). External vs. internal osteotomy in rhinoplasty. *Indian J Otolaryngol Head Neck Surg.*, 59(1), 9-12. DOI: 10.1007/s12070-007-0002-9
- Tirelli, G., Tofanelli, M., Bullo, F., Bianchi, M., Robiony, M. (2015). External osteotomy in rhinoplasty: Piezosurgery vs osteotome. *Am J Otolaryngol.*, 36(5), 666-671. DOI: 10.1016/j.amjoto.2015.05.006
- Tsikopoulos, A., Tsikopoulos, K., Doxani, C., Vagdatli, E., Meroni, G., Skoulakis, C., Stefanidis, I., Zintzaras, E. (2020). Piezoelectric or Conventional Osteotomy in Rhinoplasty? A Systematic Review and Meta-Analysis of Clinical Outcomes. *ORL J Otorhinolaryngol Relat Spec.*, 82(4), 216-234. DOI: 10.1159/000506707

*Резюме***ПОРІВНЯЛЬНИЙ АНАЛІЗ ЕФЕКТИВНОСТІ РІЗНИХ МЕТОДІВ ОСТЕОТОМІЇ ПРИ ВИКОНАННІ ЗАКРИТОЇ РИНОПЛАСТИКИ****Олександр О. Карчинський¹, Андрій В. Лупир¹, Тетяна О. Карчинська²**

1 – Кафедра оториноларингології Харківський національний медичний університет, м. Харків, Україна

2 – Комунальне некомерційне підприємство «Міська поліклініка № 22» Харківської міської ради, м. Харків, Україна

Мета. Підвищення ефективності лікування хворих на первинну деформацію носового скелету з вираженим порушенням функції носового дихання, шляхом вдосконалення існуючих та розробкою нових методик відновної хірургії носу.

Матеріали та методи. У дослідження взяли участь 38 пацієнтів. Вони були поділені на дві групи по 19 пацієнтів у кожній. Статеві-віковий розподіл в обох групах був приблизно однаковим. Контрольній групі була виконана ринопластика з використанням традиційної остеотомії. Ендоназальну безперервну остеотомію виконували долотом діаметром 4 мм. Дослідницькій групі під час ринопластики була проведена комбінація п'єзоелектричної хірургії та комбінованого черезшкірного доступу. При цьому долотом 3 мм проводили бічні та поперечні латеральні остеотомії, а п'єзотомом – медіальну та поперечну дорсальні остеотомії та видаляли горб. Усім пацієнтам обох груп виконано лише первинну ринопластику закритим способом.

Результати. В обох групах вивчалися післяопераційні симптоми та ускладнення: перфорація слизової оболонки, звуження носових дихальних шляхів, кісткові нерівності, набряк повік, періорбітальні ехімози, а також загальна задоволеність пацієнтів. Симптоми оцінювали в перший день після операції, через 3 дні після операції та через 1 тиждень після лікування.

При порівнянні отриманих даних виявлено статистично значуще зниження інтра- та післяопераційних ускладнень при виконанні ринопластики п'єзоелектричним способом у поєднанні з черезшкірним доступом. Також п'єзотомна остеотомія в поєднанні з черезшкірним доступом має низку переваг перед класичною остеотомією, які полягають у зменшенні травматичних ускладнень, отриманні більш стабільних кісткових структур під час оперативного втручання, що дає краще прогнозований результат ринопластики, а отже, більшу задоволеність пацієнтів.

Висновки. Виконання комбінації п'єзотомної остеотомії з черезшкірним доступом покращує післяопераційний період пацієнтів і сприяє кращому результату ринопластики за рахунок меншої кількості ускладнень.

Ключові слова: п'єзотомія, остеотомія, ринопластика, черезшкірний, ендоназальний, ускладнення