

UDC 616.216.1-002.191-073-039-02:616.716.1:616.717.85  
<https://doi.org/10.31612/2616-4868.1.2024.05>

## RADIOLOGICAL FEATURES OF THE LOCATION OF CYSTIC FORMATIONS IN THE MAXILLARY SINUS AND THEIR RELATIONSHIP WITH ALVEOLAR BONE PATHOLOGY OF THE UPPER JAW

Volodymyr O. Shkorbotun<sup>1,2</sup>, Yaroslav S. Nachesa<sup>2</sup>, Yaroslav V. Shkorbotun<sup>1,2</sup>

1 – State Institution of Science «Research and Practical Center of Preventive and Clinical Medicine» State Administrative Department, Kyiv, Ukraine

2 – Shupyk National Healthcare University of Ukraine, Kyiv, Ukraine

### Summary

**The aim of the study.** To study the features of the location of cystic formations in the maxillary sinus based on CT scans and to determine their relationship with the pathology of the upper jaw teeth.

**Materials and methods.** The study involved the analysis of 552 head computed tomography scans of patients referred for examination by an otolaryngologist or dentist. The total number of individuals examined was 552, comprising 44.7 % females and 55.3 % males, aged 18-74 years. The investigation was conducted using the NewTom GO device with a measurement range of 155-172 mGy/cm $\pm$ 10 %, with an error of  $\pm$ 4.24 %. Statistical processing of data was carried out using the STATISTICA v.12.6 software.

**Results.** Out of 552 computed tomography images analyzed, 92 images of individual maxillary sinuses (MS) of 79 patients with single cysts were selected. They were divided into two groups. Group 1 involved patients with cysts on the lower wall of MS (n=76). Group 2 included patients with cysts on other walls (n=16). The assessment of the ratio of 4, 5, 6, 7 tooth roots of the upper jaw to the lower wall of the upper jaw showed that the protrusion frequency in Group 1 was significantly higher (42.1 %) compared to Group 2 (18.7 %). Meanwhile, the average thickness of the bone over these teeth in Group 2 was significantly greater ( $3.4 \pm 1.09$  mm) than in Group 1 ( $1.9 \pm 0.92$  mm) ( $p=0.0003$ ). In both patient groups, the greatest thickness was observed over tooth 4, and the smallest over tooth 7. Additionally, in 33.7 % of cases, the cyst was associated with involvement of deep structures of the projecting teeth and the spread of inflammation to the lower wall of MS.

**Conclusions.** Among patients referred by an otolaryngologist or dentist for CT examination to radiologically verify pathological processes in the nasal cavity, paranasal sinuses, and the upper jaw teeth, MS cysts were detected in 19.6 % of cases, with 83 % of them being localized in its lower parts. In patients with cysts located in the lower parts of MS, the roots protruding into the sinus cavity and a thinner layer of bone over them are more frequently observed compared to those where cysts are located in other areas of MS. In patients with cystic formations in the alveolar recess of MS, radiological signs of pathology of the upper jaw teeth are detected in 34 % of cases.

**Keywords:** upper respiratory tract, nasal cavity, rhinosinusitis, X-ray of paranasal sinuses, cyst, morphology, inflammatory diseases of upper respiratory tract

### INTRODUCTION

It is difficult to reliably estimate the prevalence of sinus cysts in the population due to the frequent asymptomatic course and the complexity of diagnosis during routine otolaryngological examination. Therefore, in the literature,

the frequency of this pathology varies significantly, ranging from 3.2 % to 35.6 % [3, 5, 7, 16]. Maxillary sinus (MS) cysts are the most common in the structure of paranasal sinus cysts, accounting for up to 90 % of all cases [3, 8].

The clinical picture of MS cyst does not have clear pathognomonic clinical signs and may manifest symptoms

that are characteristic of other nasal cavity and paranasal sinus pathologies. These symptoms include frequent rhinosinusitis, headaches, a feeling of pressure in the area of the paranasal sinuses, impaired nasal breathing, rhinorrhea, as well as possible lacrimation and paresthesia of certain facial areas [1, 9, 11, 15, 18]. Therefore, in some cases, the detection of a cyst may be an incidental finding during radiological examination of the head for other indications [19].

Morphologically, MS cysts are hollow formations filled with fluid, and their walls are formed by surrounding tissues. According to Schuknecht & Lindsey [17], MS cysts are divided into two groups: those arising from the mucous membrane of the sinus, and cysts of dental origin. Cysts arising from the mucous membrane are further classified as non-secreting, retention, and mucocele. This classification, with some clarifications, is mentioned in recent textbooks and guidelines [1, 2, 4, 12, 13]. Secretory retention cysts are referred to as true cysts, while non-secreting ones are called pseudocysts or lymphangiectatic.

Pathogenetically, a mucocele forms as a result of blockage of the natural drainage pathways of the paranasal sinuses. Retention or true cysts occur when the duct of a mucous gland is obstructed, leading to its distension as secretions accumulate. Non-secreting cysts (pseudocysts) develop submucosally or due to splitting of the mucoperiosteal flap with accumulation of exudate or transudate [5, 10]. The distinguishing feature of pseudocysts from others is their slow growth, predominant location on the lower wall of MS, and the ability to self-regress [5, 18].

It should be noted that reactive odontogenic cysts also exist, arising from inflammation of the tissues surrounding the tooth with subsequent spread of the process to the mucoperiosteum and the formation of retention or lymphangiectatic cysts as a result of inflammation. According to the mechanism of their formation, they are similar to retention or pseudocysts of non-odontogenic origin. However, in case of their detection, the tooth, which is the causative agent of the disease, or other pathology in the periodontal area that led to inflammatory changes in the mucoperiosteum can be clearly identified [2].

The causes of MS cyst formation are diverse and have not been fully investigated. Among them are chronic rhinosinusitis, inflammatory and allergic diseases of the upper respiratory tract, as well as infections of the oral cavity with chronic inflammation of the teeth and alveolar bone of the upper jaw [14, 15].

The above indicates the need for further etiopathogenetic studies of cystic formations in MS, especially regarding pseudocysts, to clarify the role of odontogenic inflammatory factors in their occurrence.

## THE AIM OF THE STUDY

To study the features of the location of cystic formations in MS based on CT scans and to determine their relationship with the pathology of the upper jaw teeth.

## MATERIALS AND METHODS

The study was carried out at the Department of Otorhinolaryngology of Shupyk National Healthcare University of Ukraine. The analysis of 552 computed tomography images of patients referred by an otolaryngologist or dentist for radiological verification or exclusion of diseases of the nose, paranasal sinuses, and the upper jaw teeth, was conducted.

The age of the examined patients ranged from 18 to 74 years, with a mean age of  $36.7 \pm 11.8$  years. Among them, there were 247 women (44.7 %) and 305 men (55.3 %). The NewTom GO device (Italy), equipped with a «CANON/TOSHIBA D-067SB» tube with the serial number 0D14854-J4241A3, was used for computed tomography (CT), with a measurement range of  $155-172 \text{ mGy/cm} \pm 10 \%$ , and an error of  $\pm 4.24 \%$ .

According to the analysis of 552 CT scans of patients, MS cysts were identified in 108 cases, including 17 with bilateral involvement and 29 cases with two or more cysts in one sinus.

CT results were analyzed using the Weasis Dicom Viewer software. The state of the paranasal sinuses was assessed based on their pneumatization and the presence of other radiological pathological changes.

To determine the average diameter of the cysts, two perpendicular measurements were taken, and the mean value was calculated in millimeters. The state of the ostiomeatal complex was assessed as freely passable, partially obstructed, or blocked.

The statistical analysis was carried out by non-parametric statistical methods using the Mann-Whitney and Chi-square tests. The arithmetic mean (M) and the standard deviation (m) were used to describe data with a normal distribution. Statistical processing of the data was carried out using the STATISTICA v.12.6 software.

## RESULTS

Based on the analysis of 552 CT scans, the following pathologies were diagnosed: acute rhinosinusitis – 208 (37.7 %), chronic rhinosinusitis, including polyposis – 101 (18.3 %), maxillary sinus cysts – 108 (19.6 %), fungal formations – 12 (2.2 %). Pathological changes in the paranasal sinuses were not found in 123 (22.2 %) patients.

Out of 108 patients with cystic formations in the paranasal sinuses, we selected 79 CT scans with single cysts in MS. Taking into account the presence of bilateral

involvement in 13 patients, the analysis included 92 CT scans of individual sinuses.

Regarding the localization of cysts in MS, the distribution was as follows: in 3 cases (3.3 %), they were located on the upper wall of the sinus, in 4 cases (4.3 %) – on the medial wall, in 9 cases (9.8 %) – on the anterior wall, while in the remaining 76 cases (82.6 %), the cyst was localized in the lower parts of the sinus.

The dominance of cyst placement in the lower parts of the sinus indicates a potential influence of reactive

inflammation from teeth on the alveolar bone of the upper jaw and the mucoperiosteum of MS.

To determine the possible origin of the cysts, we analyzed the presence of pathology in the upper jaw teeth located in the projection area of the lower wall of MS, in particular, the alveolar recess – teeth 4, 5, 6, 7 of the upper row, which can be referred to as projecting.

The results of the analysis of the state of projecting teeth in patients with MS cysts, depending on their localization on the sinus walls, are presented in table 1.

Table 1

### The pathology of upper jaw teeth in patients with maxillary sinus cysts, depending on localization on the sinus walls

Criteria for pathology of projecting teeth of the upper jaw	Number of sinuses N (%)	Localization of cysts in MS		MS ostium	
		Lower wall	Other walls	Passable	Partially obstructed
Absence of dental pathology	47 (51.1 %)	35 (38 %)	12 (13.1 %)	38 (41.3 %)	9 (9.8 %)
Superficial caries that does not extend to the pulp and periodontium of the tooth	14 (15.2 %)	10 (10.9 %)	4 (4.3 %)	11 (12 %)	3 (3.2 %)
Caries with spread of the process to the tooth pulp, periapical cysts, periodontitis	15 (16.3 %)	15 (16.3 %)	0 (0 %)	14 (15.2 %)	1 (1.1 %)
Teeth with filled root canals	11 (12 %)	11 (12 %)	0 (0 %)	11 (12 %)	0 (0 %)
Adentia	5 (5.4 %)	5 (5.4 %)	0 (0 %)	5 (5.4 %)	0 (0 %)
In total	92 (100 %)	76 (82.6 %)	16 (17.4 %)	79 (85.9 %)	13 (14.1 %)

As can be seen from table 1, in 31 cases (33.7 %), the identified cysts were considered odontogenic, while in the remaining 61 cases (66.3 %), they were of different origins. Odontogenic cysts included cases with deep caries spreading to the tooth pulp, periapical cysts, periodontitis, and those with root canal filling and adentia, as these conditions indicated a history of pathological processes. Cysts of non-odontogenic origin comprised all cases of cystic formations in the sinuses without radiographic signs of dental pathology or with superficial caries that did not extend to the periodontium or tooth pulp. The ostium of MS was freely passable in all examined patients, and in only 13 cases (14.1 %) it was partially obstructed. Partial obstruction

of the ostium was significantly more frequent in the group of patients with non-odontogenic cysts – 12 cases (19.7 %), compared to odontogenic cysts – 1 case (3.2 %) ( $p=0.0032$ ).

To investigate the role of potential factors contributing to occurrence of odontogenic cysts in MS, we analyzed the frequency of tooth root apices protruding into the sinus cavity and the thickness of the bone between the apices of the projecting teeth and the Schneiderian membrane in groups.

The analysis of anatomical features of the placement of projecting tooth apices in the examined sinuses, depending on the cyst origin, is presented in table 2.

Table 2

### Results of studying the frequency of protruding teeth depending on the location of detected cysts in MS

Patient groups	Protrusion of tooth roots into MS			
	Not protruding, n (%)	Protruding up to 2 mm, n (%)	Protruding 2 mm and more n (%)	Total n (%)
Group 1	44 (57.9 %)	21 (27.6 %)	11 (14.5 %)	76 (100 %)
Group 2	13 (81.3 %)	2 (12.5 %)	1 (6.2 %)	16 (100 %)
In total	57 (61.9 %)	23 (25 %)	12 (13.1 %)	92 (100 %)
p-value	$p=0.033$	$p=0.042$	$p=0.039$	

As can be seen from table 2, the frequency of individual tooth roots protruding into the sinus in patients of Group 1, where the cysts are located on the lower wall of MS, is significantly higher than in Group 2 with cysts located on other walls.

The results of measuring the thickness of the bone between the root apex of the projecting tooth and the Schneiderian membrane are presented in table 3.

The data presented in table 3 indicate that the smallest bone thickness in both examined groups is observed above the first and second molars, while the greatest thickness is found above the first premolar. It is worth noting that the average total bone thickness above the four projecting teeth in patients of Group 1, where the cysts are located on the lower sinus wall, is significantly less than in patients with cysts attached to other sinus walls (Group 2). The corresponding values are  $1.9\pm 0.92$  and  $3.4\pm 1.09$  ( $p=0.0003$ ).

Table 3

### Depth of projecting teeth in relation to the Schneiderian membrane depending on the genesis of cystic formations in MS

Patient groups	Bone thickness above the root of projecting teeth*				Total M ± m, (mm)
	Premolar 1 M ± m, (mm)	Premolar 2 M ± m, (mm)	Molar 1 M ± m, (mm)	Molar 2 M ± m, (mm)	
Group 1 (n - 76)	3.6±1.45	1.6±0.87	1.2±0.59	1.0±0.81	1.9±0.92
Group 2 (n -16)	5.4±1.23	3.7±0.79	2.3±1.17	2.1±0.98	3.4±1.09
In total, (n=92)	3.9±1.54	2.3±1.08	1.6±0.96	1.3±1.12	2.2±0.97
p-value	p=0.00014	p=0.0002	p=0.0009	p=0.0012	p=0.0003

Note— in case of adentia, the bone thickness is considered as 0

Based on the detected dental pathology, which may be the cause of cyst formation, patients were divided into two groups: Group 1 (31 patients) – with the presence of a tooth which is the causative agent of the disease, and Group 2 (61) – without dental pathology that could be considered as a cause of non-odontogenic cyst formation. The sizes of cystic formations in MS, depending on the presence of projecting tooth pathology, as a possible odontogenic cause of their occurrence, are presented in Table 4.

As can be seen from table 4, in the group of patients with dental pathology, cysts were smaller in diameter, compared to the group of patients without such pathology, 16.7±5.5 mm and 20.1±8.4 mm, respectively ( $p_{1-2}=0.036$ ).

The relationship between the size of odontogenic and non-odontogenic cysts of MS is presented in figure 1.

Table 4

### Sizes of MS cysts depending on their genesis

Patient groups	Number of patients (n)	Diameter of the detected cysts in mm
Group 1	31	16.7±5.5
Group 2	61	20.1±8.4
In total	92	18.9±7.5

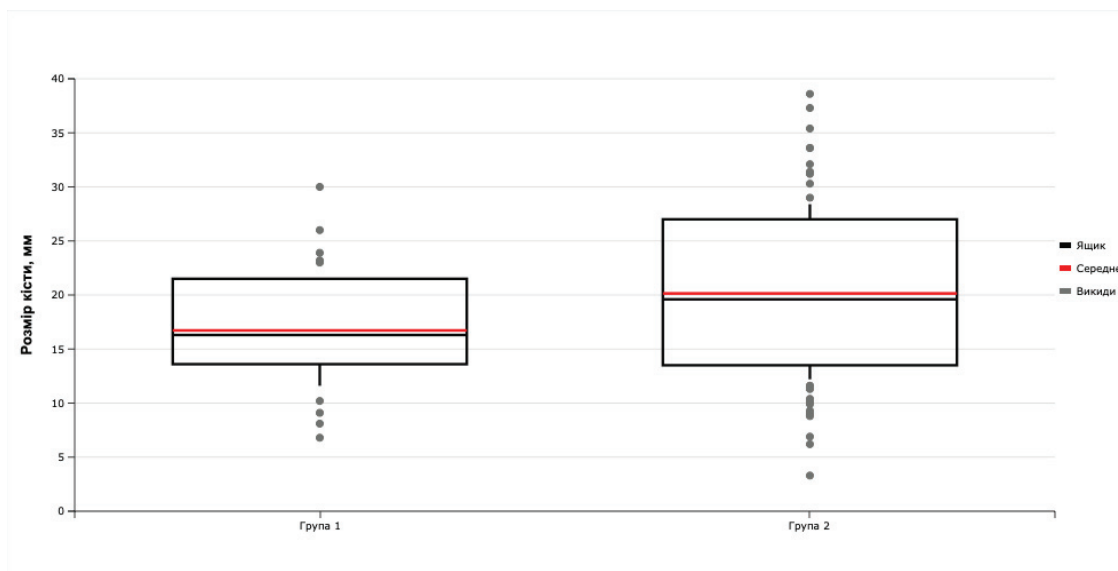


Figure 1. Dependence of the size of MS cysts on the presence of the pathology of projecting teeth of the upper jaw

Note:  $p_{1-2}=0.036$

## DISCUSSION

The prevalence of MS cysts in patients with rhinologic complaints, who were referred for radiological examination by either an otolaryngologist or a dentist to confirm the diagnosis of upper jaw pathology, was 19.6 %. Among these

cases, 85 % of the cysts were located on the lower wall of the sinus, coinciding with existing literature [3, 6].

The study of single cysts in MS found that 33.7 % of cases were associated with the involvement of deep structures related to projecting teeth, specifically premolars

and the first and second molars of the upper jaw. Similar findings were reported by Yeung (2017), who noted 37.5 % of such patients [19]. Dental lesions included caries extending to the dental pulp, periapical cysts, periodontitis, root canal filling, and missing teeth. All these conditions induce inflammation that may spread to the alveolar bone of the upper jaw and the Schneiderian membrane, thereby triggering the formation of odontogenic cysts. It is important to note that the term «odontogenic» in this context refers to cysts originating from dental inflammation, whereas in the literature, it is used to describe cysts originating directly from tooth tissues.

A comparison of the sizes of MS cysts in patients without dental pathology in the corresponding upper jaw and those with identified dental problems revealed that the former had larger cysts ( $19.8 \pm 8.2$  mm), compared to patients with dental problems ( $16.5 \pm 5.4$  mm).

This is likely due to the fact that non-odontogenic cysts are caused by chronic inflammation of the mucous membrane of the sinus, while when the teeth are affected, local inflammation occurs in the area of their projection.

The research on the anatomical structure of the alveolar recess indicates variations in bone thickness between the root apices of projecting teeth and the Schneiderian membrane. The thickness varies among individuals and specific teeth. The thinnest bone was observed above the second molar in both groups, while the greatest thickness was above the first premolar. However, the comparison group (patients with cysts on the lateral walls of MS) had greater bone thickness along the entire alveolar recess compared to the main group (patients with cysts on the lower wall of MS). The presence of roots protruding into MS was observed in both groups, with a higher percentage in the main group – 27.6 % at a depth of up to 2 mm compared to 12.5 %, and 14.5 % at a depth greater than 2 mm compared to 6.2 %. In view of the fact that dental caries is a common infectious disease that affects the deep structures of the tooth and surrounding tissues in case of untimely treatment, these anatomical features may contribute to the spread of inflammation to the mucoperiosteum of MS. Ince Yusufoglu et al. (2021) noted that involvement in the periodontal ligament and alveolar bone could lead to local thickening of the mucous membrane of MS, which is a risk factor for cyst formation [20].

These findings create the basis for further research into the inflammatory odontogenic factor in the origin of MS cysts, including pseudocysts. They also suggest the

potential use of conservative anti-inflammatory treatment following effective prophylaxis of projecting teeth in the upper jaw.

## CONCLUSIONS

1. Among patients referred by an otolaryngologist or dentist for CT examination to radiologically verify pathological processes in the nasal cavity, paranasal sinuses, and the upper jaw teeth, MS cysts were detected in 19.6 % of cases, with 83 % of them being localized in its lower parts.

2. In patients with cystic formations in MS, localized in the alveolar recess, 34 % had radiological signs of pathology in the upper jaw teeth.

3. In patients with cysts located in the lower parts of MS, the protrusion of molar and premolar roots into the sinus cavity and a thinner layer of bone above them is significantly more common (81.3 %) compared to those with cysts in other areas of MS (57.9 %).

**Perspectives of further research.** Further studies on the pathogenesis of maxillary sinus cysts at the molecular level help enhancing the effectiveness of their treatment. Specifically, investigating the role of the alveolar recess and maxillary teeth pathology could contribute to improving our understanding of the condition and potential treatment options.

## FUNDING AND CONFLICT OF INTEREST

The study was conducted as a fragment of the complex scientific projects of the Otolaryngology Department of Shupyk National Healthcare University of Ukraine «Improving methods of diagnosis and treatment of patients with pathology of the nose and paranasal sinuses», (state registration number 0122U200964; term: 2022-2026).

The article is self-funded. The authors declare no conflict of interest.

## COMPLIANCE WITH ETHICAL REQUIREMENTS

The research was conducted in accordance with the principles of the Helsinki Declaration of the World Medical Association «Ethical principles of medical research involving a person as an object of research». All study participants provided informed consent in writing to participate in the study.

## LITERATURE

1. Дитяча оториноларингологія: національний підручник / Лайко А. А. та ін. 2-ге вид., перероб. та допов. Вінниця: ТОВ «Меркьюрі-Поділля», 2022. 506 с.

2. Дитяча ринологія. Навч.-метод. посібник / під ред. Ф. Юрочка, А. Косаковського, В. Шкорботуна. Львів: Мс, 2020. 288 с.
3. Єрохіна А. О., Нікулін М. І. Кісти верхньощелепних пазух. Оптимізація хірургічного лікування. Актуальні питання сучасної медицини і фармації: зб. тез доп. наук.-практ. конф. з міжнарод. участю молодих вчених та студ., 13-17 травня 2019 р. / Запоріжжя, 2019. С. 54-55.
4. Аветиков Д. С., Яценко И. В. Современные подходы к классификации кист челюстей. Проблемы экологии та медицини. 2012. Вип. 16, № 1-2. С. 3-6.
5. Anitua E., Alkhraisat M. H., Torre A., Eguia A. Are mucous retention cysts and pseudocysts in the maxillary sinus a risk factor for dental implants? A systematic review. *Medicina Oral, Patología Oral Y Cirugía Bucal*. 2021. Vol. 26(3). P. e276. <https://doi.org/10.4317/medoral.24155>
6. Arslan İ. B., Uluyol S., Demirhan E., Kozcu S. H., Pekçevik Y., Çukurova İ. Paranasal sinus anatomic variations accompanying maxillary sinus retention cysts: a radiological analysis. *Turkish archives of otorhinolaryngology*. 2017. Vol. 55(4). P. 162. <https://doi.org/10.5152/tao.2017.2759>
7. Bal M., Berkiten G., Uyanik E. Mucous retention cysts of the paranasal sinuses. *Hippokratia*. 2014. Vol. 18(4). P. 379.
8. Beyers, J. A. Some Questions In Treatment Of Cysts Of The Maxillary Sinus. *KRS Journal of Medicine*. 2022. Vol. 2(3). P. 11-15.
9. Fokkens W. J., Lund V. J., Hopkins C., Hellings P. W., Kern R., Reitsma S., Toppila-Salmi S., Bernal-Sprekelsen M., Mullol J., Alobid I., Terezinha Anselmo-Lima W., Bachert C., Baroody F., von Buchwald C., Cervin A., Cohen N., Constantinidis J., De Gaborly L., Desrosiers M., Diamant Z., ... Zwetsloot C. P. European Position Paper on Rhinosinusitis and Nasal Polyps 2020. *Rhinology*, 2020. Vol. 58(Suppl S29). 464 p. <https://doi.org/10.4193/Rhin20.600>
10. Gardner D. G. Pseudocysts and retention cysts of the maxillary sinus. *Oral surgery, oral medicine, oral pathology*. 1984. Vol. 58(5). P. 561-567. [https://doi.org/10.1016/0030-4220\(84\)90080-x](https://doi.org/10.1016/0030-4220(84)90080-x)
11. Gonçalves E. S., Gonçalves A. G. B., da Silva Lima E., Rocha J. F., Noletto J. W., Hochuli-Vieira E. Symptomatic mucous retention cysts of the maxillary sinus: case report. *RSBO Revista Sul-Brasileira de Odontologia*. 2015. Vol. 12(2). P. 233-237.
12. Kao D. W. *Clinical maxillary sinus elevation surgery*. John Wiley & Sons., 2014. 184 p.
13. Malik N. Cysts of the «Oro-Maxillofacial Region». *Oral and Maxillofacial Surgery for the Clinician*. 2021. P. 549-575. [https://doi.org/10.1007/978-981-15-1346-6\\_27](https://doi.org/10.1007/978-981-15-1346-6_27)
14. Nascimento E. H. L., Pontual M. L. A., Pontual A. A., Freitas D. Q., Perez D. E. C. & Ramos-Perez F. M. Association between odontogenic conditions and maxillary sinus disease: a study using cone-beam computed tomography. *Journal of endodontics*. 2016. Vol. 42(10). P. 1509-1515. <https://doi.org/10.1016/j.joen.2016.07.003>
15. Nemati P., Jafari-Pozve N., Aryanezhad S. S. Association between mucous retention cyst of paranasal sinuses and nasal septum deviation. *Advances in Oral and Maxillofacial Surgery*. 2023. Vol. 10. P. 100415. <https://doi.org/10.1016/j.adoms.2023.100415>
16. Ritter A., Rozendorn N., Avishai G., Rosenfeld E., Koren I., Soudry E. Preoperative maxillary sinus imaging and the outcome of sinus floor augmentation and dental implants in asymptomatic patients. *Annals of Otolaryngology, Rhinology & Laryngology*. 2020. Vol. 129(3). P. 209-215. <https://doi.org/10.1177/0003489419883292>
17. Schuknecht H. F., Lindsay J. R. (1949). Benign cysts of the paranasal sinuses. *Archives of Otolaryngology*. 1949. Vol. 49(6). P. 609-630. <https://doi.org/10.1001/archotol.1949.03760120036004>
18. Wang J. H., Jang Y. J., Lee B. J. Natural course of retention cysts of the maxillary sinus: long-term follow-up results. *The Laryngoscope*. 2007. Vol. 117(2). P. 341-344. <https://doi.org/10.1097/01.mlg.0000250777.52882.7a>
19. Yeung A. W. K., Tanaka R., Khong P. L., von Arx T., Bornstein M. M. Frequency, location, and association with dental pathology of mucous retention cysts in the maxillary sinus. A radiographic study using cone beam computed tomography (CBCT). *Clinical oral investigations*. 2018. Vol. 22. P. 1175-1183. <https://doi.org/10.1007/s00784-017-2206-z>
20. Yusufoglu S. I., Erbasar G. N. H., Gülen O. Evaluation of the effect of periapical lesions and other odontogenic conditions on maxillary sinus mucosal thickness characteristics and mucosal appearance: A CBCT study. *Journal of Dental Research, Dental Clinics, Dental Prospects*. 2021. Vol. 15(3). P. 163. <https://doi.org/10.34172/joddd.2021.028>

## REFERENCES

1. Layko, A. A., Zabolotna, D. D., Borysenko, O. M., Gavrylenko, Yu. V., Synyachenko, V.V., Tymchuk, S. M., Kosakivska, I. A., Segal, V. V., & Shuh, L.A. (2022). Dytyacha otorinolaryngologiya [Pediatric otorhinolaryngology]. Vinnytsia: Mercury-Podillya (in Ukr.).

2. Yurochko, F., Kosakovskiy, A., & Shkorbotun, V. (2020). *Dytyacha rynologia [Pediatric rhinology]*. Lviv: Ms (in Ukr.).
3. Yerohina, A. O., Nikulin, M. I. (2019) *Kistu verchnyoschelepnyh pazuh. Optyimizaciya hirurgichnogo likuvannya. [Maxillary sinus cysts. Optimization of surgical treatment] Current issues of modern medicine and pharmacy. Zaporizhzhia, 54-55.*
4. Avetikov, D. S., & Yatsenko, I. V. (2012). *Sovremennye podhody k klassificatsii kist chelustey. [Modern approaches to the classification of jaw cysts]. Problems of ecology and medicine, 16, № 1-2, 3-6.*
5. Anitua, E., Alkhraisat, M. H., Torre, A., & Eguia, A. (2021). *Are mucous retention cysts and pseudocysts in the maxillary sinus a risk factor for dental implants? A systematic review. Medicina Oral, Patología Oral Y Cirugía Bucal, 26(3), e276. https://doi.org/10.4317/medoral.24155*
6. Arslan, İ. B., Uluyol, S., Demirhan, E., Kozcu, S. H., Pekçevik, Y., & Çukurova, İ. (2017). *Paranasal sinus anatomic variations accompanying maxillary sinus retention cysts: a radiological analysis. Turkish archives of otorhinolaryngology, 55(4), 162. https://doi.org/10.5152/tao.2017.2759*
7. Bal, M., Berkiten, G., & Uyanık, E. (2014). *Mucous retention cysts of the paranasal sinuses. Hippokratia, 18(4), 379.*
8. Beyers, J. A. (2022). *Some Questions In Treatment Of Cysts Of The Maxillary Sinus. KRS Journal of Medicine, 2(3), 11-15*
9. Fokkens, W. J., Lund, V. J., Hopkins, C., Hellings, P. W., Kern, R., Reitsma, S., ... & Witterick, I. (2020). *European position paper on rhinosinusitis and nasal polyps 2020. Rhinology: official organ of the International rhinologic society.*
10. Gardner, D. G. (1984). *Pseudocysts and retention cysts of the maxillary sinus. Oral surgery, oral medicine, oral pathology, 58(5), 561-567. https://doi.org/10.1016/0030-4220(84)90080-x*
11. Gonçalves, E. S., Gonçalves, A. G. B., da Silva Lima, E., Rocha, J. F., Noleto, J. W., & Hochuli-Vieira, E. (2015). *Symptomatic mucous retention cysts of the maxillary sinus: case report. RSBO Revista Sul-Brasileira de Odontologia, 12(2), 233-237.*
12. Kao, D. W. (Ed.). (2014). *Clinical maxillary sinus elevation surgery. John Wiley & Sons.*
13. Malik, N. (2021). *Cysts of the «Oro-Maxillofacial Region». Oral and Maxillofacial Surgery for the Clinician, 549-575. https://doi.org/10.1007/978-981-15-1346-6\_27*
14. Nascimento, E. H. L., Pontual, M. L. A., Pontual, A. A., Freitas, D. Q., Perez, D. E. C., & Ramos-Perez, F. M. (2016). *Association between odontogenic conditions and maxillary sinus disease: a study using cone-beam computed tomography. Journal of endodontics, 42(10), 1509-1515. https://doi.org/10.1016/j.joen.2016.07.003*
15. Nemati, P., Jafari-Pozve, N., & Aryanezhad, S. S. (2023). *Association between mucous retention cyst of paranasal sinuses and nasal septum deviation. Advances in Oral and Maxillofacial Surgery, 10, 100415. https://doi.org/10.1016/j.adoms.2023.100415*
16. Ritter, A., Rozendorn, N., Avishai, G., Rosenfeld, E., Koren, I., & Soudry, E. (2020). *Preoperative maxillary sinus imaging and the outcome of sinus floor augmentation and dental implants in asymptomatic patients. Annals of Otology, Rhinology & Laryngology, 129(3), 209-215. https://doi.org/10.1177/0003489419883292*
17. Schuknecht, H. F., & Lindsay, J. R. (1949). *Benign cysts of the paranasal sinuses. Archives of Otolaryngology, 49(6), 609-630.. https://doi.org/10.1001/archotol.1949.03760120036004*
18. Wang, J. H., Jang, Y. J., & Lee, B. J. (2007). *Natural course of retention cysts of the maxillary sinus: long-term follow-up results. The Laryngoscope, 117(2), 341-344. https://doi.org/10.1097/01.mlg.0000250777.52882.7a*
19. Yeung, A. W. K., Tanaka, R., Khong, P. L., von Arx, T., & Bornstein, M. M. (2018). *Frequency, location, and association with dental pathology of mucous retention cysts in the maxillary sinus. A radiographic study using cone beam computed tomography (CBCT). Clinical oral investigations, 22, 1175-1183. https://doi.org/10.1007/s00784-017-2206-z*
20. Yusufoglu, S. I., Erbasar, G. N. H., & Gülen, O. (2021). *Evaluation of the effect of periapical lesions and other odontogenic conditions on maxillary sinus mucosal thickness characteristics and mucosal appearance: A CBCT study. Journal of Dental Research, Dental Clinics, Dental Prospects, 15(3), 163. https://doi.org/10.34172/joddd.2021.028*

*Резюме***РЕНТГЕНОЛОГІЧНІ ОСОБЛИВОСТІ РОЗМІЩЕННЯ КІСТОЗНИХ УТВОРЕНЬ ВЕРХНЬОЩЕЛЕПНОГО СИНУСУ ТА ЇХ ЗВ'ЯЗОК ІЗ ПАТОЛОГІЄЮ АЛЬВЕОЛЯРНОГО ВІДРОСТКА ВЕРХНЬОЇ ЩЕЛЕПИ****Володимир О. Шкорботун<sup>1,2</sup>, Ярослав С. Начеса<sup>2</sup>, Ярослав В. Шкорботун<sup>1,2</sup>**

1 – Державна наукова установа «Науково-практичний центр профілактичної та клінічної медицини» Державного управління справами, м. Київ, Україна

2 – Національний університет охорони здоров'я України імені П. Л. Шупика, м. Київ, Україна

**Мета.** Дослідити особливості розміщення кістозних утворень у верхньощелепному синусі за КТ дослідженнями та зв'язувати їх зв'язок з патологією зубів верхньої щелепи.

**Матеріали та методи.** У роботі проаналізовано 552 комп'ютерні томограми голови пацієнтів, які були направлені на обстеження отоларингологом або стоматологом. Загальна кількість обстежених осіб складала 552, з них 44,7 % – жінки і 55,3 % – чоловіки, з віком від 18 до 74 років. Для проведення комп'ютерної томографії використовувався апарат NewTom GO з діапазоном вимірювань 155-172 мГр/см ± 10 %, з похибкою ± 4,24 %. Статистичну обробку даних проводили за допомогою програмного продукту STATISTICA v.12.6.

**Результати.** З 552 комп'ютерних томограм для аналізу було виділено 92 зображення окремих верхньощелепних синусів (ВЩС) 79 пацієнтів з одиночними кістами. Їх було розділено на дві групи: I – з кістами на нижній стінці ВЩС (n=76), II – з кістами на інших стінках (n=16). Оцінка співвідношення коренів 4, 5, 6, 7 зубів верхньої щелепи до нижньої стінки ВЩС показала, що частота випинання в I групі пацієнтів суттєво вища (42,1 %) у порівнянні з II (18,7 %). При цьому, середня товщина кістки над цими зубами в II групі була суттєво більшою ( $3,4 \pm 1,09$  мм) ніж в I-й ( $1,9 \pm 0,92$  мм) ( $p=0,0003$ ). У обох групах пацієнтів найбільша товщина спостерігалась над 4 зубом, а найменша – над 7 зубом. Крім того, у 33,7 % випадків кіста була асоційована з ураженням глибоких структур проєкційних зубів та поширенням запалення на нижню стінку ВЩС.

**Висновки.** Серед пацієнтів, направлених оториноларингологом або стоматологом на КТ-обстеження для рентгенологічної верифікації патологічних процесів в порожнині носа, приносівих синусах та зубах верхньої щелепи, в 19,6 % випадків виявляються кісти ВЩС, при чому у 83 % з них – вони локалізуються в його нижніх відділах. У пацієнтів із розташуванням кісти у нижніх відділах ВЩС, спостерігається частіше виступання коренів проєкційних зубів в порожнину пазухи та тонший шар кістки над ними, порівняно із тими, де кісти локалізуються в інших ділянках ВЩС. У пацієнтів із кістозними утвореннями ВЩС, розташованими в альвеолярній бухті, у 34 % випадків виявляються рентгенологічні ознаки патології зубів верхньої щелепи.

**Ключові слова:** верхні дихальні шляхи, носова порожнина, риносинусит, рентгенографія приносівих синусів, кіста, морфологія, запальні захворювання верхніх дихальних шляхів