

UDC 616.314.22-007.285-089.843-073-77
<https://doi.org/10.31612/2616-4868.4.2024.09>

PRIMARY AND POST-OSSEOINTEGRATION STABILITY OF SHORT (ULTRA-SHORT) IMPLANTS ON EDENTULOUS ATROPHIED DISTAL SEGMENTS OF THE MANDIBLE – AN INDICATOR OF IMMEDIATE OR DELAYED LOAD

Anatolii P. Oshurko^{1,2}, Ihor Yu. Oliinyk¹, Nataliia B. Kuzniak¹, Valentyna V. Sukhliak²

1 – Bukovinian State Medical University, Chernivtsi, Ukraine

2 – State Institution «Lugansk State Medical University», Rivne, Ukraine

Summary

Introduction. The issue of determining the possibility of immediate or long-term load on the selected type of implants, which will ensure the predictable result of their long-term functionality, remains an ongoing discussion. The results of the resonance frequency analysis, which perfectly characterize the stability of short and ultrashort implants at all stages of their osseointegration and post-osseointegration periods, can serve as such an indicator basis.

Aim. To analyze the primary and post-osseointegration stability of short (ultra-short) implants placed by the methods at the level of the cortical bone layer and subcortically in case of bone atrophy caused by acquired final dentition defects.

Materials and methods. The primary and post-osseointegration stability of thirty-nine dental short ($h = 6.5 \text{ mm} \times b = 4.0 \text{ mm} - 20$ pieces) and ultra-short ($h = 5.5 \text{ mm} \times b = 4.0 \text{ mm} - 19$ pieces) implants placed on the edentulous distal segments of the human mandible was studied. According to the clinical assessment that met the aim and objectives of this study, all patients were divided into four study groups: the first group consisted of patients with a preserved dentition who did not require dental implantation; the second group – 25-45 years old, the third group – 46-60 years old, and the fourth group – ≥ 61 years old. Using the resonance frequency analysis (RFA) method by Penguin Instruments, the results were interpreted in declarative units of measurement – the implant stability quotient (ISQ).

Results. The installed short (ultrashort) implants, according to the methodology by the level of the cortical layer of bone tissue, are characterized by their high primary stability by anti-rotational force: in the second group of the study (25-45 years old) with a mean number (M) of 87.0 and an error of the mean ($\pm m$) of ± 2.3 ISQ; in the third group (46-60 years old) – 76.4 ± 3.0 ISQ; in the fourth group (persons ≥ 61 years old) – 69.8 ± 4.8 ISQ. Low values of primary stability were obtained in implants installed by the subcortical implantation technique in the second age group of the study and amounted to 59.6 ± 2.7 ISQ with a slight increase to 66.0 ± 4.1 ISQ in the third group and 71.7 ± 4.2 ISQ in the fourth group of the study, which do not guarantee the prognosis of functional redistribution of the supra occlusion immediate load on the biological basis, with further preservation of the course of normal physiological processes in the bone tissue around the implanted implants.

Conclusions. Rehabilitation of patients with bone atrophy caused by the loss of the masticatory group of teeth is possible using short ($h = 6.5-6.0 \text{ mm}$) and ultra-short ($h = 5.5 \text{ mm}$) implants, with clinical justification for the choice of methods of immediate or post-osseointegration load, with a detailed resonance frequency analysis as a priority and reliable method – an effective indicator of their stability, at all stages of clinical rehabilitation of patients.

Keywords: short implant, resonance frequency analysis (RFA), implant stability quotients (ISQ)

INTRODUCTION

Modern clinical dentistry focuses on the search and application of methods and techniques for the rehabilitation of patients with tooth loss in the anterior aesthetic zone [10], focusing on modifications of implant connections or their surfaces [6], using combined techniques of solid autografts [16] and soft tissue management [15]. However, the use of minimally invasive techniques using short and ultrashort implants, which are a priority in the rehabilitation of edentulous patients with bone atrophy, remains underestimated. Of course, success will be possible only if the biological basis of bone tissue is understood, if it is affected by any systemic conditions of the patient [12], if the clinical surgeon is skilled in planning implantation and adequately follows the protocol for implant placement, positioning for distribution of occlusal pressure, and hygienic care of the supra construction [4].

The use of high-density osseo synthetic materials (xenografts) to compensate for the lost bone volume can ensure the primary stability of the implant and its stability and require stabilizing membranes. Therefore, the issue of choosing methods for determining the possibility of immediate or long-term load on the selected type of implants that will ensure the predictable result of their long-term functionality remains relevant. Such indicators are the results of the resonance frequency analysis [8], which perfectly characterizes the stability of even ultrashort implants at all stages of their osseointegration and post-osseointegration periods [2], as described in this study.

AIM

To analyze the primary and post-osseointegration stability of short (ultra-short) implants placed by the methods at the level of the cortical bone layer and subcortically in case of bone atrophy caused by acquired final dentition defects.

MATERIALS AND METHODS

The primary stability of thirty-nine dental short ($h = 6.5 \text{ mm} \times b = 4.0 \text{ mm} - 20$ pieces) and ultra-short ($h = 5.5 \text{ mm} \times b = 4.0 \text{ mm} - 19$ pieces) implants was determined using resonance frequency analysis (RFA) by Penguin Instruments, with the interpretation of the results in declarative units of measurement – the implant stability quotient (ISQ). Also, for analytical comparison, the stability of the implants in Newtons (Ncm), as an anti-rotational force, was determined using standard methodological torque wrenches.

Implant placement complies with the Protocols of internationally standardized implantation techniques, namely: at the level of the cortical layer – twenty-four implants and subcortical – fifteen implants, in people

aged 25-75 years, with acquired terminal defects of the dentition with severe bone atrophy, complicated by topographic and anatomical features of the mandibular canal.

Values in the range of 75 ISQ and above meant that a short (ultrashort) implant had adequate primary stability and could receive and distribute immediate load on the bone tissue of the edentulous segment. Evidence of such stability is the absence of a drop in ISQ within 1-3 days when using the immediate load technique and within 14 days in the post-osseointegration period or a change in the range of no more than 1-7 ISQ in the primary rehabilitation period.

Resonance frequency analysis was performed in accordance with the stated instructions of the above technique, with strict adherence to the methodological sequence, which requires screwing the original MultiPeg™ rod to the implant and its subsequent vibration due to the received wave of magnetic pulses generated by the device. The device measures the vibration frequency due to the rigidity in the contact zone between the bone and the implant surface and converts it into a scale value from 1 to 99 ISQ. The higher the ISQ is, the better its stability is. RFA measures implant stability as a function of boundary rigidity, which correlates with implant displacement, i.e., micro-mobility.

Seventeen patients voluntarily provided informed consent, which met the clinical assessment of the aims and objectives of this study and were divided into four study groups: the first group consisted of patients with a preserved dentition who did not require dental implantation; the second group – 25-45 years old, the third group – 46-60 years old, and the fourth group – ≥ 61 years old.

Non-parametric criteria were used to test statistical hypotheses due to the small sample size in order to identify differences in the level of the studied trait, assess possible shifts in the values of the studied trait, and identify differences in the distributions of traits. Dependent samples were compared using Wilcoxon's T-test. Multiple comparisons were performed using the Kruskal-Wallis test to assess differences between samples as their number was more significant than two, and they represented different experimental conditions in independent and unrelated observation groups [9].

RESULTS

After the installation of short (ultrashort) implants at the level of the cortical layer of bone tissue, the anti-rotation force, characterizing their high primary stability in the study group (25-45 years old) was 87.0 by the mean number (M) and the error of the mean value ($\pm m$) was ± 2.3 ISQ; group (46-60 years old) – 76.4 ± 3.0 ISQ; group (persons ≥ 61 years old) – 69.8 ± 4.8 ISQ (table 1).

Table 1

Results of the clinical experiment – rehabilitation of patients using short and ultra-short implants using the cortical implantation technique (at the level of the cortical layer), in case of bone atrophy in the distal segments of the lower jaw, complicated by the topographic and anatomical features of its canal

Groups* research	After implant placement: anti- rotation force / primary stability, M±m		Immediate load, before fixation of the supra construction, M±m		Post-osseointegration period, anti-rotational force			
	Ncm	ISQ	Ncm	ISQ	Before placing gingival formers, M±m		Before fixation of the permanent supra construction, M±m	
					Ncm	ISQ	Ncm	ISQ
Second group, 25-45 years old	62.3 ±1.5	87.0 ±2.3	61.7 ±3.3	83.0 ±2.6	Np	Np	70.0 ±0.0	92.7 ±0.9
Third group, 46-60 years old	47.3 ±3.0	76.4 ±3.0	70.0 ±0.0	88.0 ±1.0	70.0 ±0.0	86.0 ±4.1	70.0 ±0.0	90.5 ±1.0
Fourth group ≥ 61 years old	40.8 ±4.0	69.8 ±4.8	Np	Np	70.0 ±0.0	88.5 ±1.6	70.0 ±0.0	86.7 ±1.7
Reliability of the results, p	0.068	0.079	0.051	0.177	1	0.280	0.500	0.040

* Note. The first group, 25-75 years old, people with preserved dentition who do not need implantation. Np (no determination of implant stability was performed) – The operation protocol of the chosen technique is not provided for this stage.

Implant placement with high values of primary stability in Newtons (Ncm) for the second group (61.7 ± 3.3 and 70.0 ± 0.0 for the third group) prompted the use of the immediate load technique (figure 1). Realizing that the placed implants are in contact with the level of the cortical layer, which has a high density according to histomorphological characteristics, they can wedge only in it and give a false impression of high primary stability and do not provide a reliable prognosis of the further functionality of the super construction.

Therefore, the performed resonance frequency analysis (RFA) facilitates the justification for the selection of appropriate methods of rehabilitation of patients with edentulous segments of atrophied bone tissue complicated by the topographic and anatomical features of the mandibular canal. Its values in patients aged 25-45 years were 83.0 ± 2.6 ISQ, and their increase to 88.0 ± 1.0 ISQ in patients aged 46-60 years, indicating the devastation of

the trabecular layer volume due to the duration of bone atrophy in this study group, with the fixation of implants between the two cortical layers of the buccal and lingual sides.

Our detailed analysis of bone density, as described in previous scientific papers, does not justify the use of immediate load with short ($h = 6.5$ mm X $b = 4.0$ mm) and ultrashort ($h = 5.5$ mm X $b = 4.0$ mm) implants in people aged ≥ 61 years old. However, the provided postoperative conditions and marker metabolic control of bone tissue during the osseointegration period (3-4 months) make it possible to use them even in people aged ≥ 61 years old, as evidenced by the values of 88.5 ± 1.6 ISQ before the installation of gingival formers, for the formation of a soft tissue barrier – the epithelial ring, followed by its keratinization and a slight decrease to 86.7 ± 1.7 ISQ before fixation of the permanent dental implant supra construction (figure 2).

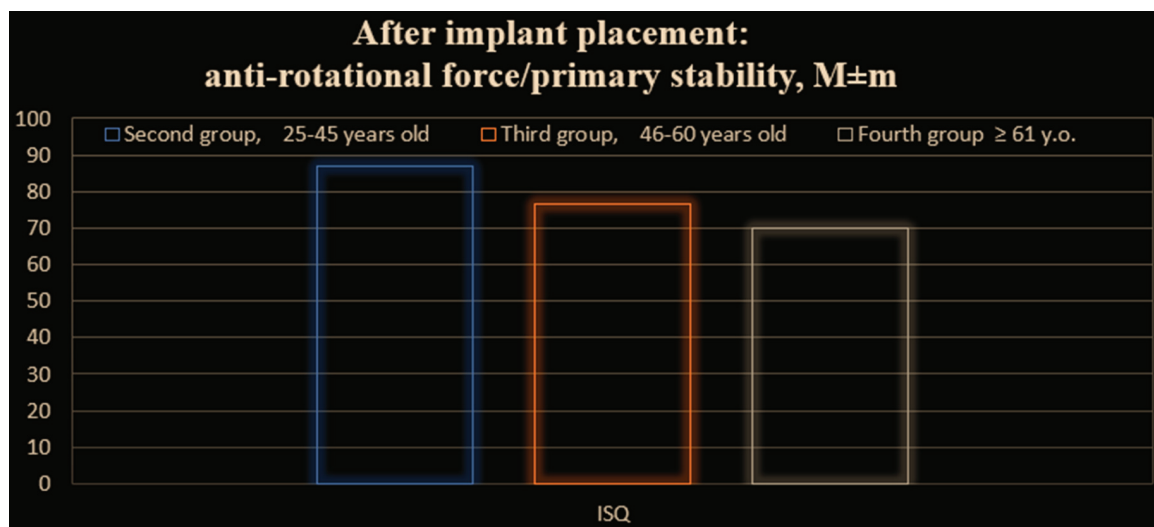


Figure 1. Results of the primary stability (ISQ) of short and ultra-short implants using the cortical implantation technique (by the level of the cortical layer).

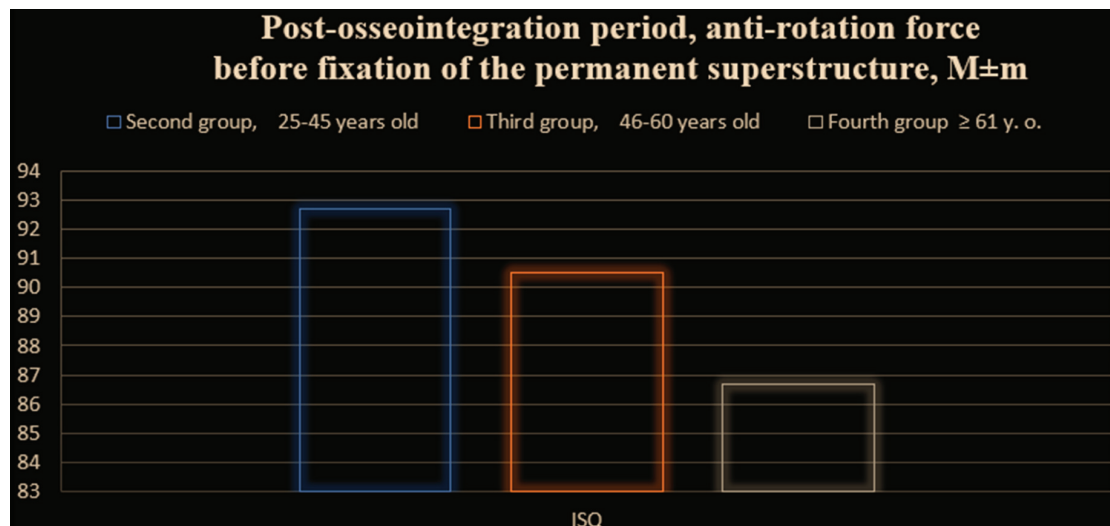


Figure 2. Results of the post-osseointegration stability (ISQ) of short and ultra-short implants using the cortical implantation technique (by the level of the cortical layer).

Although the system torque wrenches used to measure the anti-rotational force are limited to 70 Ncm and are marked «∞», this analysis indicates that a high post-osseointegration result was achieved. The obtained RFA values also characterize the high biological adaptation of artificial dental organs (implants) in the second study group (25–45 years) at 92.7 ± 0.9 ISQ and their increase to 90.5 ± 1.0 ISQ in the third group (46–60 years), which is confirmed by statistical analysis, where the reliability of these results is $p \leq 0.040$.

The saturation of the medical market with implant systems and comprehensive marketing progress are

not always objective identifiers for clinical guidance. Also, depending on the quantitative morphology of the bone tissue and its qualitative characteristics, it is necessary to postpone the rehabilitation of edentulous patients, choosing, in turn, minimally invasive methods of restoring the chewing efficiency of the dentition. In order to determine the clinical priority, we studied the postoperative stability of fifteen microdental artificial organs (titanium implants) using the subcortical implantation technique in conditions of limited bone supply due to a mixed form of bone atrophy (table 2).

Table 2

Results of the clinical experiment – rehabilitation of patients using short and ultra-short implants using the subcortical implantation technique in case of bone atrophy in the distal segments of the lower jaw, complicated by the topographic and anatomical features of its canal

Groups* research	After implant installation: anti-rotation strength / primary stability, M±m		Post-osseointegration period, anti-rotational power			
	Ncm	ISQ	Before placing gingival formers, M±m		Before fixation of the permanent supra construction, M±m	
			Ncm	ISQ	Ncm	ISQ
Second group, 25-45 years old	36.0±1.9	59.6±2.7	40.0±0.0	93.4±1.4	40.0±0.0	90.0±0.7
Third group, 46-60 years old	32.5±1.4	66.0±4.1	40.0±0.0	90.5±1.0	40.0±0.0	88.0±0.9
Fourth group ≥ 61 years old	35.8±1.5	71.7±4.2	40.0±0.0	88.8±1.4	40.0±0.0	87.0±1.7
Reliability of the results, p	0.178	0.052	0.500	0.052	0.500	0.089

* Note. The first group, 25-75 years old, people with preserved dentition who do not need implantation.

It is clear that the primary stability of implants is primarily ensured by compliance with the protocol of bone tissue preparation, which in most cases no longer corresponds to typical biological characteristics and directly depends on the time of tooth loss with variability in the age periods of ontogenetic development. In fact, the subcortical implantation technique involves a cut osteotomy path in its sequence to reduce compression pressure on both bone tissue and

morphological structures of the closely located mandibular canal. Another feature is that subcortical implants, even short ones, have a cut edge in their shape for post-osseointegration cortical suturing. Therefore, it is practically impossible to ensure the primary stability of short subcortical implants, even in highly mineralized and, even more so, atrophied bone tissue in the edentulous distal segments of the mandible, as evidenced by the graphic image (figure 3).

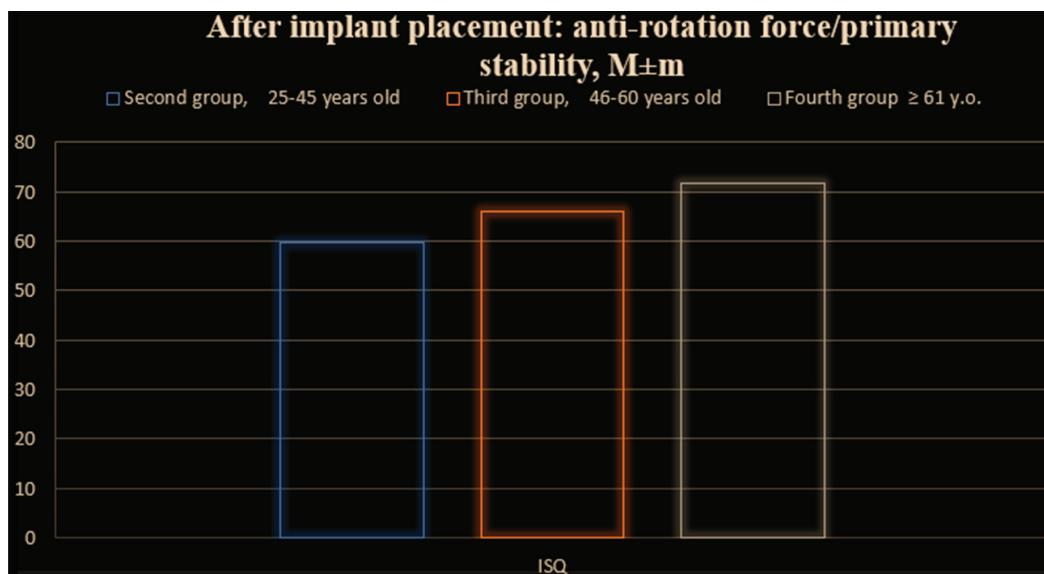


Figure 3. Results of primary stability (ISQ) of short and ultra-short implants using the subcortical implantation technique.

The generally accepted value of 40 Ncm of primary stability (PS), regulated for the immediate load protocol, was not achieved in any of the 15 intraosseous subcortical implants in the study group (see table 2). Anti-rotation strength in the second age group of the study was 59.6 ± 2.7 ISQ, with a slight increase to 66.0 ± 4.1 ISQ in the third group and 71.7 ± 4.2 ISQ in the fourth group of the study.

Even careful adherence to the stages of the implant bed formation protocol and the obtained Ps value does not guarantee the prediction of functional redistribution of the supra occlusion load to the biological basis, with the subsequent preservation of the course of normal physiological processes in the bone tissue around the implants. Therefore, the clinical rationale is to ensure appropriate conditions during the osseointegration period for the acquisition of qualitative and quantitative

characteristics of the biological matrix, that is, not only its tight surrounding of the rough surface of the implant but also the organization of cortical crosslinking as the most stable membrane (barrier) protection.

The highest result of post-osseointegration stability was obtained during resonance frequency analysis in the second age group (25-45 years) with values of 93.4 ± 1.4 ISQ with a slight decrease to 90.5 ± 1.0 ISQ in the third and 88.8 ± 1.4 ISQ in the fourth study groups (figure 4).

For the clinical formation of the epithelial barrier ring around the gingival formers and, subsequently, for the coverage of the prosthetic base of the supra construction, 21-24 days were allocated, after which the Ps of the implants were re-determined.

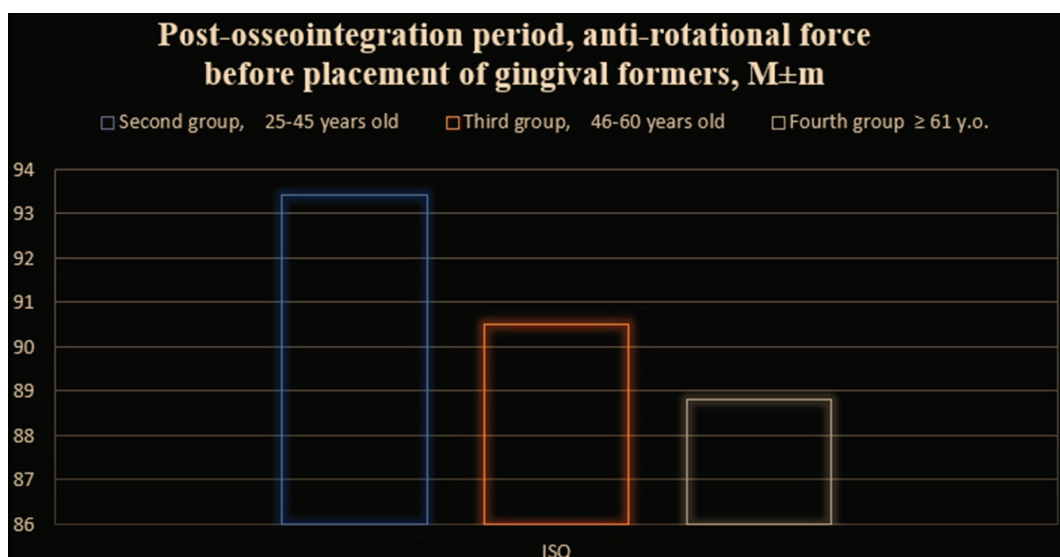


Figure 4. The results of post-osseointegration stability (ISQ) of short and ultra-short implants using the subcortical implantation technique before the placement of gingival formers.

There was a decrease in RFA values (figure 5) by 3.4 ISQ units in the youngest second age group, by 2.5 ISQ units in the third, and only by 1.8 ISQ units in people ≥ 61 years old (fourth study group), the statistical mean deviations (errors) of which are presented in table 2. The decrease in post-osseointegration stability in subcortical implants is natural because, for the proper anchorage of gingival formers, it is necessary to provide access to the implant platform by decorticating the newly created bone not only to the appropriate depth but also to the appropriate width. Each iatrogenic effect leads to minor and controlled metabolic processes of localized remodeling. The younger the age group, the higher the

rate of their growth, followed by a decline in activity after reaching a stabilized functional state.

The determination of post-osseointegration stability in the generally accepted terms (3-4 months) before the placement of gingival formers is an evidentiary basis for the correctness of the direction of clinical priority for the broader introduction of minimally invasive techniques using short ($h = 6.5 \text{ mm} \times b = 4.0 \text{ mm}$) and ultra-short ($h = 5.5 \text{ mm} \times b = 4.0 \text{ mm}$) subcortical implants with the possibility of full functional rehabilitation of patients with severe bone atrophy caused by the loss of the masticatory group of teeth and complicated by the topographic and anatomical features of the mandibular canal but without immediate load.

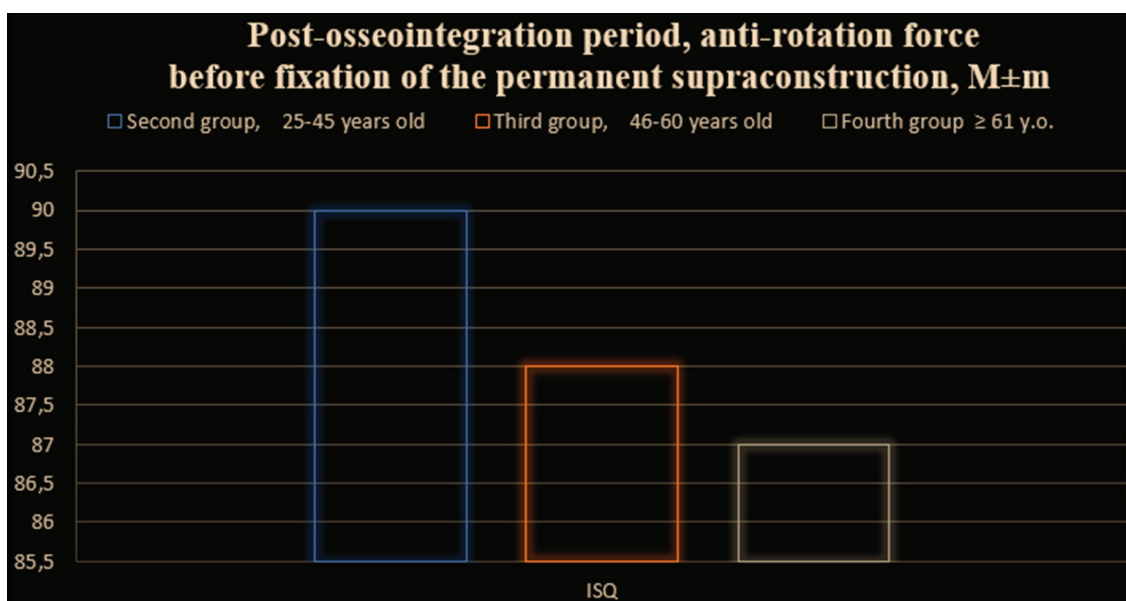


Figure 5. The results of post-osseointegration stability (ISQ) of short and ultra-short implants using the subcortical implantation technique before fixation of the permanent supra construction.

DISCUSSION

Most modern scientists study the results of bone tissue augmentation [1] using various methods of controlling its regeneration [7, 11], which in the early stages do not ensure the stability of implants but only partially compensate for the lost bone tissue volume according to clinical needs and reconstructive prognoses. After all, the bone graft goes through four stages of bone remodeling in its immediate completeness, namely: activation (3 days), resorption (30 days), formation (100 days), and mineralization (190 days), under conditions of stability and its protection and adequate blood supply [13]. Therefore, providing an immediate load on the implant in the first stage (activation) of remodeling and the presence of bone deficiency is a dubious clinical prognosis.

The work of the authors [5] shows 100 % engraftment and functionality of narrow titanium-zirconium mini-implants in the edentulous mandible using the immediate

load technique, in case of obtaining their primary stability of at least 35 Ncm and remote load when the anti-rotational force was below 35 Ncm, with an installation distance of five millimeters. In our opinion, this technique is the method of choice and can serve as the basis for removable and conditionally removable prosthetic supra constructions since their placement in the distal parts of edentulous atrophied bone tissue is not justified.

According to the results of a systematic review and meta-analysis [3], researchers emphasize that removable implant-supported dentures are no less effective than fixed dentures in terms of clinical results, and inpatient rehabilitation of patients with edentulous mandible is a well-accepted method of treatment in terms of patients' oral health. We do not dispute this conclusion, but in the above work, the authors of [5] do not consider the continued progressive development of bone atrophy «from inactivity» in the distal edentulous segments as the implants were positioned centripetally.

Original studies [17] using the video image correlation method were conducted to determine the micromovements of the dental implant and the bone base, and they show that there are significant differences between these two objects. The linear type of displacement of a dental implant refers to the linear modulus of elasticity of bone tissue under regular occlusion forces. The authors prove that the main factor affecting the type and magnitude of implant micromovements is the bone tissue surrounding the implant. However, we can only agree with this argument during the osseointegration period, given that there is no proper osseous architectonic structure around the implant but signs of corticalization, as will be described in our next publications.

In our previous works, we presented clinically tested methods of resonance frequency analysis as an indicator of rapid and complete rehabilitation of patients with bone atrophy caused by acquired terminal dentition defects with complicated topography of the mandibular canal(s) [14], which formed the basis of this study.

CONCLUSIONS

1. Rehabilitation of patients with bone atrophy caused by the loss of the masticatory group of teeth is possible using short ($h = 6.5\text{-}6.0$ mm) and ultrashort ($h = 5.5$ mm) implants, with the choice of methods of immediate or post-osseointegration load, with detailed resonance frequency analysis as a priority and reliable method – an effective indicator of their stability, at all stages of clinical rehabilitation of patients.

2. Ensuring the restoration of chewing efficiency with fixed orthopedic structures supported by short and ultrashort implants, using the method of cortical implantation (at the level of the cortical layer) of immediate load in case of bone atrophy in the edentulous distal segments of the mandible, is a reasonable clinical approach in patients of the second and third study groups, subject to careful adherence to the completeness of the clinical protocol.

3. The distribution of occlusal pressure on short (ultrashort) implants placed by the immediate load subcortical implantation technique is impossible due to the

absence of cortical crosslinking as the primary stabilizing biological barrier.

4. Decrease in post-osseointegration stability (ISQ) of subcortical implants after placement of gingival formers, under normal biological conditions, occurs due to the disconnection of cortical bone crosslinking, providing access to the implant platform, followed by localized remodeling processes.

The prospect of further research is to study the effect of compensatory mechanisms of the elastic modulus on peri-implant hard tissues with changes in their histomorphological characteristics.

FUNDING AND CONFLICT OF INTEREST

The authors declare that there was no conflict of interest at any stage of the research work and in its content in general, and assure that this work was conducted as part of the initiative research work of the Department of Histology, Cytology, and Embryology of Bukovinian State Medical University «Structural and functional features of tissues and organs in ontogeny, patterns of variant, constitutional, sex-age and comparative human morphology,» state registration number 0121U11012.

COMPLIANCE WITH ETHICAL REQUIREMENTS

This work is a fragment of a clinical experiment of the planned research topic «Substantiation of rehabilitation of patients with bone atrophy complicated by topographic and anatomical features of the mandibular canal,» with mandatory preliminary review by the Biomedical Ethics Commission of Bukovinian State Medical University and approval in the form of Protocol No. 2 of 21.10.2021. The clinical experiment was conducted in compliance with the main provisions of the GCP (1996), the Council of Europe Convention on Human Rights and Biomedicine (04/04/1997), the World Medical Association Declaration of Helsinki on the Ethical Principles of Scientific Medical Research Involving Human Subjects (1964-2013), Order of the Ministry of Health of Ukraine No. 690 of 23.09.2009 (as amended by Order of the Ministry of Health of Ukraine No. 190 of 31.01.2023).

REFERENCES

- Anitua, E. (2022). Implant Dentistry from One-Way Direction to the Reversibility of the Osseointegration. *Eur J Dent.*, 16(2), 464. <https://doi.org/10.1055/s-0041-1740219>.
- Antequera-Diaz, R., Quesada-García, M.P., Vallecillo, C., Vallecillo-Rivas, M., Muñoz-Soto, E., & Olmedo-Gaya, M.V. (2022). Intra- and inter-operator concordance of the resonance frequency analysis. A cross-sectional and prospective clinical study. *Clin Oral Investig.*, 26(11), 6521-6530. <https://link.springer.com/article/10.1007/s00784-022-04601-y>.

3. Borges, G.A., Barbin, T., Dini, C., Maia, L.C., Magno, M.B., Barão, V.A.R., & Mesquita, M.F. (2022). Patient-reported outcome measures and clinical assessment of implant-supported overdentures and fixed prostheses in mandibular edentulous patients: A systematic review and meta-analysis. *J Prosthet Dent.*, 127(4), 565-577. <https://doi.org/10.1016/j.prosdent.2020.11.005>.
4. Cheung, M.C., Hopcraft, M.S., & Darby, I.B. (2021). Dentists' preferences in implant maintenance and hygiene instruction. *Aust Dent J.*, 66(3), 278-288. <https://doi.org/10.1111/adj.12831>.
5. Curado, T.F.F., Silva, J.R., Nascimento, L.N., Leles, J.L.R., McKenna, G., Schimmel, M., & Leles, C.R. (2023). Titanium-zirconium mini implants for mandibular overdentures: a 1-year randomized clinical trial on implant survival and peri-implant outcomes. *Clinical Oral Implants Research*, 34(8), 769-782. <https://doi.org/10.1111/clr.14102>.
6. D'Orto, B., Chiavenna, C., Leone, R., Longoni, M., Nagni, M., & Capparè, P. (2023). Marginal Bone Loss Compared in Internal and External Implant Connections: Retrospective Clinical Study at 6-Years Follow-Up. *Biomedicines*, 11(4), 1128. <https://doi.org/10.3390/biomedicines11041128>.
7. Degli Esposti, M., Changizi, M., Salvatori, R., Chiarini, L., Cannillo, V., Morselli, D., & Fabbri, P. (2022). *ACS Applied Polymer Materials*, 4(6), 4306-4318. <https://doi.org/10.1021/acsapm.2c00270>.
8. Guerrero-González, M., Monticelli, F., Saura, García-Martín, D., Herrero-Climent, M., Ríos-Carrasco, B., Ríos-Santos, J.V., & Fernández-Palacín, A. (2020). Reliability of the Resonance Frequency Analysis Values in New Prototype Transepithelial Abutments: A Prospective Clinical Study. *Int J Environ Res Public Health*, 17(18), 6733. <https://doi.org/10.3390/ijerph17186733>.
9. Jiang, J. (2022). *Applied Medical Statistics* (1st ed.). Wiley. Retrieved from <https://www.perlego.com/book/3449554/applied-medical-statistics-pdf> (Original work published 2022).
10. Kan, J.Y.K., Rungcharassaeng, K., Kamolroongwarakul, P., Lin, G.H., Matsuda, H., Yin, S., Wang, H.L., Tarnow, D., & Lozada J. L. (2023). Frequency of screw-retained angulated screw channel single crown following immediate implant placement and provisionalization in the esthetic zone: A cone beam computed tomography study. *Clin Implant Dent Relat Res.*, 25(5), 789-794. <https://doi.org/10.1111/cid.13227>.
11. Korsch, M., Alt, K.W., & Mock, F.R. (2023). Frozen Stored Teeth: Autogenous Dentin as an Alternative Augmentation Material in Dentistry. *Bioengineering (Basel)*. 10(4), 456. <https://doi.org/10.3390/bioengineering10040456>.
12. Monje, A., Kan, J.Y., & Borgnakke, W. (2023). Impact of local predisposing/precipitating factors and systemic drivers on peri-implant diseases. *Clin Implant Dent Relat Res.*, 25(4), 640-660. <https://doi.org/10.1111/cid.13155>.
13. Oshurko, A.P., Oliinyk, I.Yu., Yaremchuk, N.I., & Makarchuk, I.S. (2021). Morphological features of bone tissue in «disuse atrophy» on the example of a segment of the human lower jaw: clinical experience of treatment. *Biomedical and biosocial anthropology*, 42, 5-11. <https://doi.org/10.31393/bba42-2021-01>.
14. Oshurko, A.P., Oliinyk, I.Yu., Kuzniak, N.B., & Herasym, L.M. (2023). Resonance frequency analysis – indicator of post-implantation morphology of mandibular bone tissue. *Modern Medical Technology*, 4(59), 70-75. doi: [https://doi.org/10.34287/MMT.4\(59\).2023.9](https://doi.org/10.34287/MMT.4(59).2023.9).
15. Prati, C., Zamparini, F., Canullo, L., Pirani, C., Botticelli, D., & Gandolfi, M.G. (2020). Factors Affecting Soft and Hard Tissues Around Two-Piece Transmucosal Implants: A 3-Year Prospective Cohort Study. *The International journal of oral & maxillofacial implants*, 35 5, 1022-1036. <https://doi.org/10.11607/jomi.7778>.
16. Starch-Jensen, T., Vitenson, J., Deluiz, D., Østergaard, K.B., & Tinoco, E.M.B. (2022). Lateral Alveolar Ridge Augmentation with Autogenous Tooth Block Graft Compared with Autogenous Bone Block Graft: a Systematic Review. *J Oral Maxillofac Res.*, 13(1), e1. <https://www.ejomr.org/JOMR/archives/2022/1/e1/v13n1e1.pdf>.
17. Száva, D.T., Száva, A., Száva, J., Gálfi, B., & Vlase, S. (2022). Dental Implant and Natural Tooth Micro-Movements during Mastication-In Vivo Study with 3D VIC Method. *J Pers Med.*, 12(10), 1690. <https://doi.org/10.3390/jpm12101690>.

Резюме

ПЕРВИННА ТА ПОСТОСТЕОІНТЕГРАЦІЙНА СТАБІЛЬНІСТЬ КОРОТКИХ (УЛЬТРАКОРОТКИХ) ІМПЛАНТАТІВ НА БЕЗЗУБИХ АТРОФОВАНИХ ДИСТАЛЬНИХ СЕГМЕНТАХ НИЖНЬОЇ ЩЕЛЕПИ – ІНДИКАТОР НЕГАЙНОГО, АБО ВІДТЕРМІНОВАНОГО ЇХ НАВАНТАЖЕННЯ

Анатолій П. Ошурко^{1,2}, Ігор Ю. Олійник¹, Наталія Б. Кузняк¹, Валентина В. Сухляк²

1 – Буковинський державний медичний університет, м. Чернівці, Україна

2 – Державний Заклад «Луганський державний медичний університет», м. Рівне, Україна

Вступ. Актуальною дискусією залишається питання щодо визначення можливості негайного чи віддаленого навантаження на обраний вид імплантатів, які забезпечуватимуть прогнозований результат їх тривалої функціональності. Такою індикаторною основою можуть стати отримані результати проведеного резонансно-частотного аналізу, які досконало характеризують стабільність коротких та ультракоротких імплантатів на всіх етапах їх остеоінтеграційного та постостеоінтеграційного періодів.

Мета. Провести аналіз первинної та постостеоінтеграційної стабільності коротких (ультракоротких) імплантатів, що встановлені за методиками по рівню кортикального шару кісткової тканини та субкортикально, при атрофії кісткової тканини, зумовленої набутими кінцевими дефектами зубних рядів.

Матеріали та методи. Досліджено первинну та постостеоінтеграційну стабільність у тридцяти дев'яти дентальних коротких ($h = 6,5 \text{ mm} \times b = 4,0 \text{ mm} - 20 \text{ шт.}$) й ультракоротких ($h = 5,5 \text{ mm} \times b = 4,0 \text{ mm} - 19 \text{ шт.}$) імплантатів, встановлених на беззубих дистальних сегментах нижньої щелепи людини. За клінічною оцінкою, що відповідає меті та завданням даної роботи, всіх пацієнтів розділено на чотири групи дослідження: першу групу склали пацієнти зі збереженим зубним рядом, які не потребували дентальної імплантації; другу групу – 25-45 років, третю групу – 46-60 років та четверту групу – ≥ 61 року. Методом резонансно-частотного аналізу (RFA) техніки Penguin Instruments, проведено інтерпретацію результатів у декларативних одиницях вимірювання – коефіцієнта стабільності імплантату (ISQ).

Результати. Встановлені короткі (ультракороткі) імплантати, за методикою по рівню кортикального шару кісткової тканини, антиротативною силою характеризують свою високу первинну стабільність: у другій групі дослідження (25-45 років), що складає за середнім числом (M) – 87,0 та похибки середнього значення ($\pm m$) – $\pm 2,3 \text{ ISQ}$; у третій групі (46-60 років) – $76,4 \pm 3,0 \text{ ISQ}$; у четвертій групі (особи ≥ 61 року) – $69,8 \pm 4,8 \text{ ISQ}$. Низькі значення первинної стабільності отримано в імплантатах, що були встановлені за методикою субкортикальної імплантації у другій віковій групі дослідження, та склали $59,6 \pm 2,7 \text{ ISQ}$ з незначним зростанням до $66,0 \pm 4,1 \text{ ISQ}$ у третій групі та $71,7 \pm 4,2 \text{ ISQ}$ у четвертій групі дослідження, що не гарантують прогнозу функціонального перерозподілу супраоклюзійного негайного навантаження на біологічну основу, з подальшим збереженням перебігу нормальних фізіологічних процесів у кістковій тканині навколо встановлених імплантатів.

Висновки. Реабілітація пацієнтів із атрофією кісткової тканини, зумовленою втратою жувальної групи зубів є можливою, використовуючи короткі ($h = 6,5-6,0 \text{ mm}$) та ультракороткі ($h = 5,5 \text{ mm}$) імплантати, за клінічним обґрунтуванням обрання методик негайного чи постостеоінтеграційного навантаження, при детальному резонансно-частотному аналізі, як пріоритетному та достовірному методі ефективному індикаторі їх стабільності, на всіх етапах клінічної реабілітації пацієнтів.

Ключові слова: короткий імплантат, резонансно-частотний аналіз (RFA), одиниці стабільності імплантата (ISQ)