

ANALYSIS OF DIFFERENCES IN PRIMARY CHRONIC RHINOSINUSITIS ENDOTYPES BASED ON OSTEITIS ASSESSED USING GLOBAL OSTEITIS SCORING SCALE (GOSS)

Iriana Maharani¹, Meliantha Tandiono¹, Yuyun Yueniwati², Nanik Setijowati³

¹Department of Otorhinolaryngology Head and Neck Surgery, Saiful Anwar General Hospital, Medical Faculty, Brawijaya University, Malang, Indonesia

²Department of Radiology, Saiful Anwar General Hospital, Medical Faculty, Brawijaya University, Malang, Indonesia

³Department of Public Health, Medical Faculty, Brawijaya University, Malang, Indonesia

Abstract

Introduction. Mucosal inflammation in primary chronic rhinosinusitis (CRS) is divided into type 2 and non-type 2 (type 1 and 3). This can induce bone remodeling leading to osteitis. As many as 36-53% of CRS patients have osteitis, which makes CRS difficult to cure. Eosinophilic inflammation is considered to have a more severe impact on bone remodeling than neutrophilic inflammation, but there has been no research thus far that has shown any correlation between endotypes and osteitis in primary CRS.

Aim. The aim of this study is to analyze the differences in primary CRS endotypes based on osteitis assessed using the Global Osteitis Scoring Scale (GOSS).

Materials and methods. A cross-sectional analytic observational study involving 33 primary CRS patients was conducted. The endotype was determined by measuring the biomarker protein levels in the uncinate process mucosa using the Enzyme-linked Immunosorbent Assay (ELISA) method. Paranasal sinus wall osteitis was evaluated by Computed Tomography (CT) scan and calculated based on GOSS.

Results. There was a significant difference in the laterality of paranasal sinus pathology, the presence of nasal polyp, eosinophil cationic protein (ECP) level, and interferon (IFN) γ level between no-to-mild and moderate-to-severe osteitis groups ($p < 0.05$). The mean GOSS in the type 2 group was significantly higher than in the non-type 2 group ($p = 0.004$).

Conclusions. Type 2 primary CRS patients have greater osteitis scores than non-type 2 patients, signifying the more profound inflammation of type 2 compared to the non-type 2. It is possible that ECP plays a role in the severity of osteitis in primary CRS patients, though its the exact role requires more research in the future.

Keywords: chronic rhinosinusitis, endotype, eosinophil cationic protein, global osteitis scoring scale, osteitis

INTRODUCTION

Rhinosinusitis is an inflammatory condition of the mucosa of the nasal cavity and paranasal sinuses. Rhinosinusitis is very common throughout the world, thus contributing as a global health problem. Based on its duration, rhinosinusitis is said to be chronic if the symptoms occur for more than 12 weeks. The prevalence of chronic rhinosinusitis (CRS) in the world, based on symptoms is around 5.5-28% [1]. From 2021 data, 29% of patients who came to the Rhinology clinic at Dr. Saiful Anwar General Hospital were diagnosed with CRS. Current theory states

that the cause of CRS is multifactorial, which includes an interaction between environmental factors and the host's immune system [1, 2]. Currently, three types of mucosal inflammation are recognized in primary CRS, each mediated by specific immune cells and cytokines. According to research by Stevens et al., regarding the relationship between endotype and phenotype in CRS, type 1 inflammation is characterized by the detection of the interferon (IFN)- γ , type 2 is the Charcot-Leyden crystal (CLC) and/or eosinophil cationic protein (ECP), while type 3 is the interleukin (IL) 17A protein biomarker [3]. Indeed, type 2 is the most researched and studied type of CRS mucosal inflammation,

because it is considered to have a more severe remodeling impact compared to type 1 and type 3 (non-type 2) [4].

Osteitis is inflammation of the bones of the paranasal sinus walls without any bone marrow involvement. Epidemiologically, as many as 36-53% of CRS patients will experience osteitis [5]. The old theory states that osteitis in CRS occurs due to the same infectious process as osteomyelitis in long bones. However, the theory then developed that osteitis was an inflammatory bone reaction caused by local inflammation of the sinonasal mucosa. This osteitis has a significant impact, causing CRS to become recurrent, difficult to cure, and is associated with increased disease severity and therapy failure [6]. The biomolecular mechanism of osteitis in CRS is actually still not completely clear. However, it is believed that the inflammatory process in the sinonasal mucosa is the main key to the occurrence of metaplasia in adjacent bones. This inflammatory process involves various immunological mechanisms which are very important in the occurrence of bone remodeling in the course of CRS. However, among the various cells, cytokines, growth factors, and pathways that are activated to increase bone metabolism leading to osteitis, the eosinophilic inflammatory mechanisms seem to be prominent [7]. Diagnosis of osteitis in CRS patients is made based on histopathological examination or imaging [8].

There are many grading systems based on Computed Tomography (CT) scans proposed to quantify osteitis, but the Global Osteitis Scoring Scale (GOSS) is currently the most widely applied system in CRS. The presence of osteitis, which further complicates disease control, has driven efforts to develop more specific management strategies for CRS with osteitis. However, no study has directly examined the association between primary CRS endotypes and osteitis severity.

AIM

The aim of this study was to analyze differences in primary chronic rhinosinusitis (CRS) endotypes based on the severity of osteitis, as assessed using the Global Osteitis Scoring Scale (GOSS).

MATERIALS AND METHODS

This research used a quantitative approach with observational methods using a cross sectional design, by examining the endotypes and osteitis in primary CRS patients. This study was conducted at Dr. Saiful Anwar General Hospital Malang and Biomedical Laboratory of Brawijaya Medical Faculty Malang from December 2021 to October 2022. Subjects were selected using consecutive sampling. This study was approved by the Health Research Ethics Commission Dr. Saiful Anwar General Hospital Malang (400/067/K.3/102.7/2022).

The inclusion criteria for this study were adult patients aged >18 years, who met the diagnosis criteria for primary CRS based on symptoms and clinical features according to European Position Paper on Rhinosinusitis and Nasal Polyps (EPOS) 2020. Patients with CRS involving only the posterior group of paranasal sinuses, who had undergone a previous Functional Endoscopic Sinus Surgery (FESS) procedure, and who had used corticosteroids or antibiotics within 4 weeks before specimen collection were excluded from this study. In this study, we need a baseline to find out the normal cut-off value of each biomarker in order to determine the endotype within the study group, which was done by examining normal nasal tissues taken from patients without sinus involvement proven from CT scan evaluation before procedure. Patients with allergic rhinitis and patients who used corticosteroids or antibiotics within 4 weeks before specimen collection were excluded from the baseline group of this study. The endotypes were determined by measuring IFN- γ (type 1), ECP and CLC (type 2), and IL-17A (type 3) levels, of the uncinate process mucosa using the Enzyme-linked Immunosorbent Assay (ELISA) method. The biomarker protein level of the CRS sample is considered to be positive if it is higher than the 90th percentile of the biomarker protein levels in all baseline samples [3].

Paranasal sinus wall osteitis was evaluated by CT scan and calculated based on GOSS. GOSS for all of our samples was measured by the same researcher and one radiologist from our hospital. Osteitis is defined as loss of bone definition/ hyperostosis/ new bone formation or signal heterogeneity overlying each sinus wall. The grading per sinus was as follows:

Grade 1: less than 50% of the sinus wall involved and osteitis <3 mm wide;

Grade 2: less than 50% of the sinus wall involved and osteitis 3-5 mm wide;

Grade 3: less than 50% of the sinus wall involved and osteitis wider than 5 mm, OR greater than 50% of the sinus wall involved and osteitis <3 mm wide;

Grade 4: greater than 50% of the sinus wall involved and osteitis 3-5 mm wide;

Grade 5: greater than 50% of the sinus wall involved and osteitis thicker than 5 mm;

Each sinus was given a grade ranging from 0 to 5. The scores of all 10 sinuses (right and left frontalis, anterior ethmoidal, posterior ethmoidal, maxillary, and sphenoidal) were added, producing a total GOSS (range: 0-50) [9].

The differences in primary CRS endotypes based on GOSS were analyzed using the Mann-Whitney U test. A p-value <0.05 and 95% Confidence Interval (CI) were considered to be statistically significant. All of the

analysis was performed with Statistical Package for the Social Sciences (SPSS) 29 software for Mac.

RESULTS

We obtained 33 primary CRS subjects and 8 normal mucosa samples. The mean age of the 33 CRS subjects was 38.36 ± 15.27 , with 12 males and 21 females. The mean duration of subjects experiencing nasal complaints was 91.21 ± 110 weeks, with the most common main complaint being nasal obstruction. Based on CT scan examination, 22 (66.7%) subjects experienced bilateral sinus involvement, whereas based on endoscopic examination, nasal polyps were seen in 17 (51.5%) subjects.

From the tissue ELISA examination, the mean level of biomarker protein IFN- γ was 20.27 ± 5.53 pg/ml, CLC was 0.49 ± 0.36 ng/ml, ECP was 353.32 ± 132.86 pg/ml, and IL-17A was 49.92 ± 33.56 pg/ml. The 90th percentile of baseline tissue biomarker protein levels was 19.297 pg/ml for IFN- γ , 0.685 ng/ml for CLC, 380.743 pg/ml for ECP, and 48.36 pg/ml for IL-17A. Type 1 or type 3 was determined if the level of IFN- γ or IL-17A exceeds the 90th percentile of baseline level. Type 2 was determined if the level of CLC and/or ECP exceeds the 90th percentile of baseline level. In determining the endotype in this study, we

referred to the same methods that has been conducted by Stevens et al. [3]. Of the 33 CRS patients, the prevalence of single types was 30.30% for type 1, 39.39% for type 2, and 21.21% for type 3. The remainder consisted of mixed type of mucosal inflammation: mixed type 2/3 at 3.03% and mixed type 1/2/3 at 6.06%. Further recalculation was performed to determine the most dominant endotype based on the highest percentage difference between each biomarker and the 90th percentile of the baseline level. All the mixed-endotype samples were type 3. The endotype pattern of the CRS samples in this study was then re-grouped into type 2 and non-type 2, based on the highest increment of each endotype biomarkers, which was 39.39% and 60.61%, respectively.

Osteitis calculations on CT scan based on GOSS are shown in Figure 1. The mean GOSS value obtained from the 33 CRS patients in this study was 16.06 ± 10.115 , while the median was 14, with a minimum value of 3 and a maximum value of 41. Osteitis assessed based on the total GOSS can also be expressed in terms of severity, being classified as insignificant osteitis (<5), mild (5-20), moderate (>20-35) and severe (>35) degrees [9]. Of the total 33 samples, 15.15% of the patients were classified with insignificant osteitis, while 51.52% had mild osteitis, 30.30% had moderate and 3.03% of the patients had severe degrees (Figure 2).

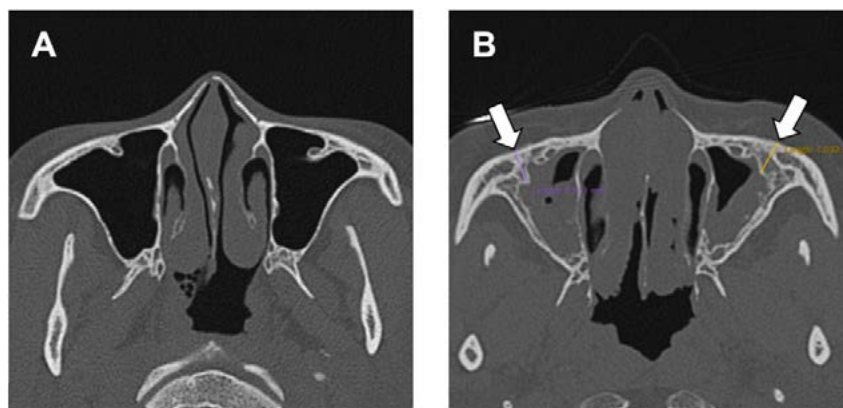


Figure 1. Axial CT scan: (A) Normal patient maxillary sinus; (B) Primary CRS patient with osteitis of the maxillary wall, the greatest thickness indicated by the arrows.

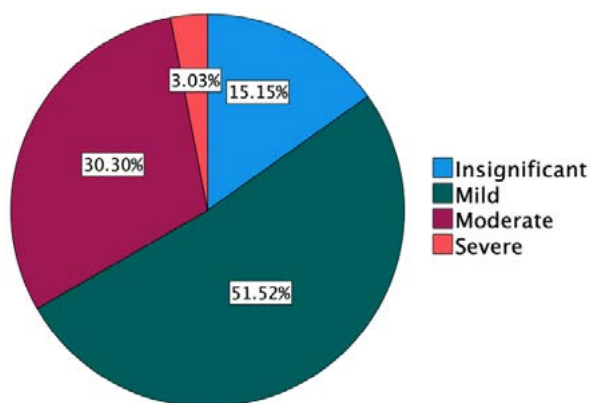


Figure 2. Pie chart of osteitis severity in primary CRS patients according to GOSS.

There was no significant difference in the characteristics of age, sex, duration of complaint, main complaint, and biomarker protein level of CLC and IL-17A in the CRS patients between no-to-mild and moderate-to-severe osteitis groups, with p values >0.05 . There was a significant difference in laterality of paranasal sinus pathology ($p=0.005$), nasal polyps ($p=0.0014$), ECP ($p=0.007$), and IFN- γ ($p=0.041$) in the CRS patients between no-to-mild and moderate-to-severe osteitis groups, ($p<0.05$; Table 1). Based on the results of the comparison test, there was also a significant difference in the mean GOSS value between endotypes of primary CRS patients (non-type 2 and type 2), with a p value of 0.004 ($p<0.05$) (Table 2).

Table 1

Characteristics and Biomarker Protein Levels of Primary CRS patients Based on Osteitis Severity according to GOSS

Variable	All (n=33)	Osteitis		p-value
		No to mild (n=22)	Moderate to severe (n=11)	
Age (years)	38.36 ± 15.27	39.59 ± 14.85	35.91 ± 16.54	0.359 ^a
Sex				
Male	12 (36.4)	10 (45.5)	2 (18.2)	0.249 ^b
Female	21 (63.6)	12 (54.4)	9 (81.8)	
Duration of complaint (weeks)	91.21 ± 110	86.59 ± 103.59	100.45 ± 126.64	0.893 ^a
Main complaint				
Nasal obstruction	18 (54.5)	11 (50)	7 (63.6)	0.758 ^c
Rhinorrhea	8 (24.2)	5 (22.7)	3 (27.3)	
Headache	4 (12.1)	3 (13.6)	1 (9.1)	
Facial pain	2 (6.1)	2 (9.1)	0 (0)	
Orbital edema	1 (3)	1 (4.5)	0 (0)	
Laterality of paranasal sinus pathology				
Unilateral	11 (33.3)	11 (50)	0 (0)	0.005 ^b
Bilateral	22 (66.7)	11 (50)	11 (100)	
Nasal polyp				
Absent	16 (48.5)	15 (68.2)	1 (9.1)	0.001 ^d
Present	17 (51.5)	7 (31.8)	10 (90.9)	
Type 2 protein biomarkers				
CLC (ng/ml)	0.49 ± 0.36	0.47 ± 0.26	0.54 ± 0.53	0.516 ^a
ECP (pg/ml)	353.32 ± 132.86	310.44 ± 123.24	439.07 ± 111.63	0.007 ^c
Non-type 2 protein biomarkers				
IFN-γ (pg/ml)	20.27 ± 5.53	21.34 ± 6.05	18.13 ± 3.66	0.041 ^a
IL-17A (pg/ml)	49.92 ± 33.56	53.75 ± 36.55	42.25 ± 26.5	0.26 ^a

Nb. ^aMann-Whitney U Test; ^bFisher's Exact Test; ^cKruskal-Wallis Test; ^dChi-Square Test; ^eIndependent Samples T Test.

Table 2

Comparison of GOSS Values between Type 2 and Non-Type 2 Primary CRS Patients

Osteitis	All (n=33)	Endotype		p-value
		Non-type 2 (n=20)	type 2 (n=13)	
GOSS	16.06 ± 10.12	11.55 ± 6.96	23 ± 10.5	0.004 ^a

^aMann-Whitney U Test.

DISCUSSION

Rhinosinusitis, according to EPOS 2020, is an inflammation of the mucosa of the nasal cavity and paranasal sinuses. It is said to be CRS if symptoms occur for more than 12 weeks. The latest classification divides CRS into primary and secondary. In primary CRS, endotypes (mucosal inflammatory type) are divided into type 2 and non-type 2 (type 1 and type 3) [1]. Remodeling in CRS, which is caused by a type of mucosal inflammation, can occur in both tissue and bone in the form of osteitis [7, 10]. Bones with osteitis can release inflammatory mediators which results in persistent edema in the overlying mucosa and cause therapeutic failure in CRS [6, 11]. Inflamed mucosa of nasal cavity and paranasal sinuses is the main key to periosteal reactions, which causes metaplasia of adjacent bones, resulting in osteitis in the walls of the paranasal sinuses (inflammatory bone reaction). By far, eosinophilic inflammation is the most researched and studied, because it is considered to have a more severe remodeling impact compared to neutrophilic inflammation [4]. However, the direct

association between endotypes and osteitis in primary CRS has not yet been fully explained [7].

In this study, according to the degree of osteitis, 15.15% of patients were classified as having insignificant osteitis, 51.52% had mild osteitis, 30.30% had moderate osteitis, and 3.03% had severe osteitis. Al-Madani et al., stated that there were 10 (20%) patients with insignificant osteitis, 23 (46%) mild, 9 (18%) moderate, and 8 (16%) severe osteitis. The results of the studies above cannot be compared directly because this study comprised all primary CRS patients regardless of the presence of nasal polyps, while the study by Al-Madani et al. only included CRS patients with diffuse sinonasal polyposis, so the sample criteria are different [12].

Type 1 mucosal inflammation is characterized by the detection of protein biomarker IFN-γ, type 2 by CLC and/or ECP, while type 3 by IL-17A [3]. The percentage of single type 1, 2, and 3 mucosal inflammation was found to be 30.30%, 39.39%, and 21.21%. Apart from that, mixed types of mucosal inflammation were also found, namely types 2/3 and 1/2/3 at 3.03% and 6.06%, respectively. Stevens et al.

stated that the percentage of type 2 mucosal inflammation was greater than non-type 2 mucosal inflammation in CRS patients [3], however these results were not in accordance with those of this study. In Western countries, 80% of CRS with nasal polyps (CRSwNP) are characterized by type 2 mucosal inflammation, which is also predominant in CRS without nasal polyps (CRSnNP). However, this differs from findings in Asia, where type 2 and non-type 2 mucosal inflammation are found in similar proportions in CRSwNP. In China itself, type 2 mucosal inflammation in CRSwNP was found to be 20% in Chengdu, 60% in Beijing. The results of several studies mentioned above further confirm the existence of geographic variability in the distribution of types of CRS mucosal inflammation, even within a single country [13-15]. The results in this study appear to be more in line with the pattern of CRS mucosal inflammation types in Asian countries compared to Western countries.

In this study, there was a significant difference in laterality of paranasal sinus pathology, nasal polyp, ECP and IFN- γ between no-to-mild and moderate-to-severe osteitis groups with p values of 0.005; 0.0014; 0.007 and 0.041, respectively ($p < 0.05$). Georgalas et al., in their research, stated that CRSwNP showed a greater percentage of osteitis than CRSnNP (75% vs 55%, $p = 0.04$) [9]. According to Wu et al., osteitis occurs as a result of an imbalance in bone production and resorption mediated by the bone morphogenic protein (BMP) signaling pathway. The expression of BMP-7 and BMP-9 along with their receptors, BMPRI1A and BMPRI2, which have pro-osteoblastic effects, is said to be decreased in CRSwNP. This decrease in osteoblastic activity, accompanied by an increase in acid phosphatase type (ACP) 5, is significantly associated with bone turnover imbalance leading to osteitis in CRSwNP [16]. The inflammatory bone reaction in pathology involving both sides of the paranasal sinuses (bilateral) will be greater than in pathology involving only one side of the paranasal sinuses (unilateral), due to differences in the surface area of the mucosa attached to the bone. However, research conducted on the CRS rabbit model showed that 52% of specimens experienced changes in the contralateral paranasal sinus bone, although no disease was found in the mucosa on that side [17]. The bony Haversian canal experiences widening and increased vascularization in CRS. This allows inflammatory mediators to migrate and spread, so that they can cause changes in bones that are located far from the location of the primary mucosal inflammation [11].

To date, there has been no literature or research that directly discusses the relationship between ECP and the pathophysiology of osteitis in CRS. However, several studies have explained the relationship between eosinophil inflammation in CRS and the occurrence of osteitis, and ECP will be released only by activated eosinophils [18]. Miyake et al. and Feldman et al. described the influence of P-glycoprotein (P-gp) in the pathophysiology of osteitis under eosinophilic inflammation. P-gp can directly

increase the secretion of T-helper (Th) 2 cytokines in local tissues [19, 20]. Gunel et al. stated that eosinophilic inflammation is also able to trigger bone changes through growth differentiation factor (GDF) 5 and exostosis (EXT) 1 [21]. In the study by Khalmuratova et al. and Kong et al., it is stated that eosinophils produce Th2 cytokines, including IL-4, IL-5, and IL-13, which play a role in regulating the activity of osteoblasts and osteoclasts, thereby resulting in neo-osteogenesis by increasing runt-related transcription factor (RUNX) 2 and receptor activator of nuclear factor kappa-B ligand (RANKL) expression [22, 23]. In a study by Snidvongs et al., a higher median osteitis score was associated with higher tissue and serum eosinophilia [24]. So far, there has been no research that directly explains the relationship of CLC to the pathophysiology of osteitis. Similar to ECP, the role of CLC can be indirectly explained through the role of eosinophils in causing osteitis.

IFN- γ is a biomarker for type 1 CRS, which is also thought to play a role in the pathophysiology of osteitis. However, several previous studies have shown inconsistencies. Kong et al. reported that IFN- γ concentrations had a positive, but not significant, correlation with RANKL concentrations [23]. On the other hand, Khalmuratova et al. stated that IFN- γ was not significant in increasing RUNX2 expression [22]. The difference in IFN- γ levels, which was significantly higher in the no-to-mild osteitis group compared to moderate-to-severe osteitis in this study, is not yet sufficient to conclude a relationship between IFN- γ and osteitis. Further research is needed to confirm the exact role of IFN- γ in the pathophysiology of osteitis in CRS.

Analysis results on GOSS values showed that there was a statistically significant difference in mean GOSS values between the type 2 and non-type 2 primary CRS in this study ($p = 0.004$). The pathophysiology of bone remodeling in CRS can occur in both type 2 and non-type 2, but involves different molecular pathways. Snidvongs et al. stated that patients with osteitis had significantly higher serum eosinophil concentrations [24]. Mehta et al. also obtained similar results, stating that increased blood and sputum eosinophil concentrations in asthma patients were significantly associated with mucosal thickening and bone changes in the paranasal sinuses [25]. Thus, the results of this study confirm that more severe osteitis tends to occur in patients with type 2 CRS, where eosinophilic inflammation predominates.

CONCLUSIONS

Type 2 primary CRS patients have greater osteitis scores than non-type 2 patients, signifying the more profound inflammation of type 2 compared to that of non-type 2. It is possible that ECP plays a role in the severity of osteitis in primary CRS patients, in which the exact role requires more research in the future.

Perspectives for further research. Future studies should explore the mechanistic link between eosinophil cationic protein (ECP) and osteitis in primary chronic rhinosinusitis (CRS) through molecular and histopathological analyses. Longitudinal investigations with larger and more diverse populations are warranted to clarify causal relationships between CRS endotypes and bone remodeling. Additionally, integrating advanced imaging modalities and quantitative biomarker profiling may improve diagnostic precision and guide personalized therapeutic approaches for CRS patients with osteitis.

COMPLIANCE WITH ETHICAL REQUIREMENTS

The analysis of differences in primary chronic rhinosinusitis endotypes based on osteitis assessed using Global Osteitis Scoring Scale (GOSS) was approved

by the Health Research Ethics Commission Dr. Saiful Anwar General Hospital Malang, approval number: 400/067/K.3/102.7/2022.

FUNDING AND CONFLICT OF INTEREST

This study received no specific funding. The authors declare no conflicts of interest.

AUTHOR CONTRIBUTIONS

Maharani I.^{A, B, C, D, E, F}

Tandiono M.^{A, B, C, D, E, F}

Yueniwati Yu.^{B, D, E, F}

Setijowati N.^{C, E, F}

REFERENCES

1. Fokkens, W. J., Lund, V. J., Hopkins, C., Hellings, P. W., Kern, R., Reitsma, S., et al. (2020). European position paper on rhinosinusitis and nasal polyps 2020. *Rhinology*, 58(Suppl 29), 1464.
2. Grayson, J. W., Hopkins, C., Mori, E., Senior, B., & Harvey, R. J. (2020). Contemporary classification of chronic rhinosinusitis beyond polyps vs no polyps. *JAMA Otolaryngology Head & Neck Surgery*, 146(9), 831838. <https://doi.org/10.1001/jamaoto.2020.1453>
3. Stevens, W. W., Peters, A. T., Tan, B. K., Klingler, A. I., Poposki, J. A., Hulse, K. E., et al. (2019). Associations between inflammatory endotypes and clinical presentations in chronic rhinosinusitis. *Journal of Allergy and Clinical Immunology: In Practice*, 7(8), 28122820. <https://doi.org/10.1016/j.jaip.2019.05.009>
4. Staudacher, A. G., Peters, A. T., Kato, A., & Stevens, W. W. (2020). Use of endotypes, phenotypes, and inflammatory markers to guide treatment decisions in chronic rhinosinusitis. *Annals of Allergy, Asthma & Immunology*, 124(3), 318325. <https://doi.org/10.1016/j.anai.2020.01.013>
5. Lee, J. T., Kennedy, D. W., Palmer, J. N., Feldman, M., & Chiu, A. G. (2006). The incidence of concurrent osteitis in patients with chronic rhinosinusitis: A clinicopathological study. *American Journal of Rhinology*, 20(3), 278282. <https://doi.org/10.2500/ajr.2006.20.2857>
6. Snidvongs, K., Sacks, R., & Harvey, R. J. (2019). Osteitis in chronic rhinosinusitis. *Current Allergy and Asthma Reports*, 19(5), 24. <https://doi.org/10.1007/s11882-019-0855-5>
7. Khalmuratova, R., & Shin, H.-W. (2021). Crosstalk between mucosal inflammation and bone metabolism in chronic rhinosinusitis. *Clinical and Experimental Otorhinolaryngology*, 14(1), 4349. <https://doi.org/10.21053/ceo.2020.00416>
8. Biedlingmaier, J. F., Whelan, P., Zoarski, G., & Rothman, M. (1996). Histopathology and CT analysis of partially resected middle turbinates. *Laryngoscope*, 106(1), 102104.
9. Georgalas, C., Videler, W., Freling, N., & Fokkens, W. (2010). Global osteitis scoring scale and chronic rhinosinusitis: A marker of revision surgery. *Clinical Otolaryngology*, 35(6), 455461.
10. Lee, K., Tai, J., Lee, S. H., & Kim, T. H. (2021). Advances in the knowledge of the underlying airway remodeling mechanisms in chronic rhinosinusitis based on the endotypes: A review. *International Journal of Molecular Sciences*, 22(3), 910. <https://doi.org/10.3390/ijms22020910>
11. Bhandarkar, N. D., Mace, J. C., & Smith, T. L. (2011). The impact of osteitis on disease severity measures and quality of life outcomes in chronic rhinosinusitis. *International Forum of Allergy & Rhinology*, 1(5), 372378.
12. Al-Madani, A. M., Helal, S. M., Khalifa, H. M., & Abdelnaby, M. M. (2016). Impact of osteitis and biofilm formation and correlation between both in diffuse sinonasal polyposis in Egyptian adults: A prospective clinical and histopathologic study. *Alexandria Journal of Medicine*, 52(3), 243250.
13. Kato, A., Peters, A. T., Stevens, W. W., Schleimer, R. P., Tan, B. K., & Kern, R. C. (2022). Endotypes of chronic rhinosinusitis: Relationships to disease phenotypes, pathogenesis, clinical findings, and treatment approaches. *Allergy*, 77(3), 812826. <https://doi.org/10.1111/all.15074>

14. Tan, B. K., Klingler, A. I., Poposki, J. A., Stevens, W. W., Peters, A. T., Suh, L. A., et al. (2017). Heterogeneous inflammatory patterns in chronic rhinosinusitis without nasal polyps in Chicago, Illinois. *Journal of Allergy and Clinical Immunology*, 139(2), 699703.
15. Wang, X., Zhang, N., Bo, M., Holtappels, G., Zheng, M., Lou, H., et al. (2016). Diversity of T helper cytokine profiles in patients with chronic rhinosinusitis: A multicenter study in Europe, Asia, and Oceania. *Journal of Allergy and Clinical Immunology*, 138(5), 13441353.
16. Wu, D., Nocera, A. L., Mueller, S. K., Finn, K., Libermann, T. A., & Bleier, B. S. (2019). Osteitis is associated with dysregulated pro-osteoblastic activity in patients with nasal polyps. *Laryngoscope*, 129(1), 102109. <https://doi.org/10.1002/lary.27581>
17. Khalid, A. N., Hunt, J., Perloff, J. R., & Kennedy, D. W. (2002). The role of bone in chronic rhinosinusitis. *Laryngoscope*, 112(11), 19511957.
18. Zrinski, R. T., & Dodig, S. (2011). Eosinophil cationic protein: Current concept and controversies. *Biochemia Medica*, 21(2), 111121.
19. Miyake, M. M., & Nocera, A. L. (2018). P-glycoprotein and chronic rhinosinusitis. *World Journal of OtorhinolaryngologyHead and Neck Surgery*, 4(3), 169174. <https://doi.org/10.1016/j.wjorl.2018.07.002>
20. Feldman, R. E., Lam, A. C., Sadow, P. M., & Bleier, B. S. (2013). P-glycoprotein is a marker of tissue eosinophilia and radiographic inflammation in chronic rhinosinusitis without nasal polyps. *International Forum of Allergy & Rhinology*, 3(9), 684687.
21. Günel, C., Bleier, B. S., Bozkurt, G., & Eliyatkin, N. (2017). Microarray analysis of the genes associated with osteitis in chronic rhinosinusitis. *Laryngoscope Investigative Otolaryngology*, 2(6), 427433. <https://doi.org/10.1002/lary.26414>
22. Khalmuratova, R., Shin, H.-W., Kim, D. W., & Park, J.-W. (2019). Interleukin-13 and interleukin-17A contribute to neo-osteogenesis in chronic rhinosinusitis by inducing RUNX2. *EBioMedicine*, 46, 330341. <https://doi.org/10.1016/j.ebiom.2019.07.035>
23. Kong, I. G., Kim, D. K., Eun, K. M., Yang, S. K., Kim, M., Oh, H., & Kim, D. W. (2020). Receptor activator of nuclear factor κ B ligand is a biomarker for osteitis of chronic rhinosinusitis. *International Forum of Allergy & Rhinology*, 10(3), 364373. <https://doi.org/10.1002/alr.22481>
24. Snidvongs, K., McLachlan, R., Chin, D., Pratt, E., Sacks, R., Earls, P., et al. (2012). Osteitic bone: A surrogate marker of eosinophilia in chronic rhinosinusitis. *Rhinology*, 50(3), 299305.
25. Mehta, V., Campeau, N. G., Kita, H., & Hagan, J. B. (2008). Blood and sputum eosinophil levels in asthma and their relationship to sinus computed tomographic findings. *Mayo Clinic Proceedings*, 83(6), 671678.

Резюме

АНАЛІЗ ВІДМІННОСТЕЙ У ПЕРВИННИХ ЕНДОТИПАХ ХРОНІЧНОГО РИНОСИНУСИТУ НА ОСНОВІ ОСТЕЇТУ, ОЦІНЕНОГО ЗА ГЛОБАЛЬНОЮ ШКАЛОЮ ОЦІНЮВАННЯ ОСТЕЇТУ (GOSS)

Іріана Махарані¹, Меліанта Тандіоно¹, Ююн Юсніваті², Нанік Сетіджоваті³

¹Відділення оториноларингології, хірургії голови та шиї, Загальна лікарня Саїфул Анвар, Медичний факультет, Університет Бравіджая, м. Маланг, Індонезія

²Відділення радіології, Загальна лікарня Саїфул Анвар, Медичний факультет, Університет Бравіджая, м. Маланг, Індонезія

³Відділення громадського здоров'я, Медичний факультет, Університет Бравіджая, м. Маланг, Індонезія

Вступ. Запалення слизової оболонки при первинному хронічному риносинуситі (ХРС) поділяється на тип 2 та не тип 2 (типи 1 і 3). Це може спричинити ремоделювання кісткової тканини, що призводить до остеїту. Приблизно 36-53% пацієнтів із ХРС мають остеїт, що ускладнює лікування захворювання. Вважається, що еозинофільне запалення має більш виражений вплив на ремоделювання кістки, ніж нейтрофільне, однак досі не проведено жодних досліджень, які б продемонстрували кореляцію між ендотипами та остеїтом при первинному ХРС.

Мета. Метою цього дослідження було проаналізувати відмінності між ендотипами первинного ХРС на основі остеїту, оціненого за Глобальною шкалою остеїту (GOSS).

Матеріали та методи. Проведено аналітичне поперечне спостережне дослідження за участю 33 пацієнтів із первинним ХРС. Ендотип визначали шляхом вимірювання рівнів білкових біомаркерів у слизовій гачкоподібного відростка (processus uncinatus) за допомогою методу імуноферментного аналізу (ELISA). Остеїт стінки приносних пазух оцінювали за допомогою комп'ютерної томографії (КТ) та розраховували за шкалою GOSS.

Результати. Виявлено достовірні відмінності щодо латеральності патології приносних пазух, наявності носових поліпів, рівнів еозинофільного катіонного білка (ECP) та інтерферону (IFN)- γ між групами з відсутнім/легким і помірним/тяжким остеїтом ($p < 0.05$). Середнє значення GOSS у групі типу 2 було статистично значно вищим, ніж у групі не типу 2 ($p = 0.004$).

Висновки. Пацієнти з первинним ХРС типу 2 мають вищі показники остеїту, ніж пацієнти з не типу 2, що свідчить про більш виражене запалення типу 2. Імовірно, ECP відіграє роль у тяжкості остеїту при первинному ХРС, що потребує подальших досліджень для з'ясування точного механізму.

Ключові слова: хронічний риносинусит, ендотип, еозинофільний катіонний білок, глобальна шкала оцінки остеїту, остеїт

Received: 4.11.2025

Accepted: 9.01.2026